EMERGING INFECTIONS 8

Edited by
W. Michael Scheld
Division of Infectious Diseases
and International Health
University of Virginia Health System
Charlottesville, Virginia

Scott M. Hammer
Division of Infectious Diseases
Columbia University College of Physicians
and Surgeons
New York, New York

James M. Hughes
Department of Medicine
Emory University School of Medicine
Atlanta, Georgia

ASM PRESS *Washington, DC*

Address editorial correspondence to ASM Press, 1752 N Street NW, Washington, DC 20036-2904, USA

Send orders to ASM Press, P.O. Box 605, Herndon, VA 20172, USA
Phone: (800) 546-2416 or (703) 661-1593
Fax: (703) 661-1501
E-mail: books@asmusa.org
Online: estore.asm.org

Copyright © 2008 ASM Press
American Society for Microbiology
1752 N Street NW
Washington, DC 20036-2904

ISBN 978-1-55581-444-1

All Rights Reserved
Printed in the United States of America

Cover photo: Bronchiole in the lung of a young infant with fatal *Bordetella pertussis* pneumonia, showing abundant bordetellae (staining red) attached to cilia of respiratory epithelial cells and free within luminal debris. Immunoalkaline phosphatase with naphthol-fast red and hematoxylin counterstain. Original magnification, ×100. (Courtesy of Sherif R. Zaki and Christopher Paddock, National Center for Infectious Diseases, Centers for Disease Control and Prevention.)

Emerging Infections 8
Edited by W. M. Scheld, S. M. Hammer, and J. M. Hughes
© 2008 ASM Press, Washington, DC

Chapter 18

Immune Reconstitution Inflammatory Syndrome

Patrick H. P. Soentjens, Graeme Meintjes, Martyn A. French, and Robert Colebunders

The prognosis of patients with human immunodeficiency virus (HIV) infection has dramatically improved since the advent of potent antiretroviral therapy (ART), which has enabled sustained suppression of HIV replication, recovery of CD4 T-cell counts, and a substantial decrease in the frequency of opportunistic infections (OIs) and of mortality (82, 109, 133, 184, 209). However, a subgroup of recently ART-initiated patients (mostly with advanced HIV disease, with high viral loads and low CD4 T-cell counts) will exhibit paradoxical clinical deterioration, known as immune reconstitution inflammatory syndrome (IRIS), occurring days to months after the start of ART (64, 74, 75, 96, 98, 112, 159, 171, 188, 198, 243, 246, 247). Approximately one-quarter to one-third of patients initiating ART experience an IRIS event (96, 228, 247). IRIS is in the first place a result of an exuberant inflammatory response towards antigens of nonviable and viable infectious agents (98). Abundant microbial antigen promotes a greater immune response when it encounters suddenly increased numbers of functionally active antigen-specific cells after the initiation of ART (248). These responses after initiating ART can result in a spectrum of presentations ranging from paradoxical worsening of a known condition to an atypical appearance of unrecognized OIs. Other disorders of immune reconstitution, which include some autoimmune diseases and immune-mediated inflammatory diseases, may also be seen (64, 74, 95, 96, 98, 112, 159, 171, 188, 198, 243, 246, 247). IRIS is usually self-limiting, typically with substantial short-term morbidity (64, 74, 95, 96, 98, 112, 159, 171, 188, 198, 243, 246, 247). However, long-term sequelae and mortality may rarely occur, particu-

Patrick H. P. Soentjens and Robert Colebunders • Department of Clinical Sciences, Institute of Tropical Medicine, Nationalestraat 155, B-2000 Antwerp, Belgium. ***Graeme Meintjes*** • Department of Medicine, University of Cape Town, Faculty of Health Sciences, Anzio Road, Observatory 7925, Cape Town, South Africa. ***Martyn A. French*** • Department of Clinical Immunology, Royal Perth Hospital, and School of Surgery and Pathology, University of Western Australia, Perth, Western Australia, Australia.

larly when neurological structures are involved (159). In most developing countries, where free ART is becoming increasingly available and where the prevalences of advanced HIV, *Mycobacterium tuberculosis* infection (tuberculosis [TB]), cryptococcal meningitis, and Kaposi's sarcoma are very high, a clinician needs to have a high index of suspicion for these emerging inflammatory syndromes after starting ART.

TERMS

There are many synonyms for IRIS (48, 57, 96, 243): immune reconstitution syndrome, immune reconstitution, restoration, or recovery disease, immunorestitution disease, immune rebound illness, and immune response reactions. Paradoxical inflammatory syndromes similar to those seen in HIV-infected patients have also been described in non-HIV-infected patients following treatment for TB or leprosy (40, 45, 238, 258). In patients following corticosteroid withdrawal, recovery of neutropenia after chemotherapy, withdrawal of immunosuppression in transplant patients, or engraftment of stem cell transplantation and in pregnant women, similar inflammatory conditions have been reported in relation to immune recovery (15, 47, 48, 254, 255).

INCIDENCE

In three large retrospective studies, up to 30% of ART responders developed one or more inflammatory syndromes consistent with IRIS (96, 228, 245). One study reported 182 episodes of IRIS: the most frequently reported associated infections were localized varicella-zoster virus (22%), TB (20%), nontuberculous mycobacterial (NTM) infection (17%), cytomegalovirus (CMV; 12%), and cryptococcal infection (6%) (247). The manifestations of IRIS with the greatest associated morbidity and mortality are seen in patients with advanced HIV disease with TB, NTM, and cryptococcosis (121, 159). Cutaneous exacerbations of viral diseases, such as herpes simplex virus, varicella-zoster virus, and human papillomavirus, are even more frequently reported but are self-limiting and are not an important public health concern. In contrast, all other manifestations of IRIS are quite rare (Table 1).

PATHOGENESIS

Previous clinicopathological studies of single, or small groups of, patients strongly suggested that IRIS results from the restoration of a cellular immune response against pathogen-specific antigens that causes immunopathology in tissues infected by the pathogen (95, 98). This is most clear for mycobacterial IRIS. Thus, IRIS provoked by active or previously treated TB or NTM infections is associated with an increase in circulating T cells reacting with mycobacterial antigens, which has been demonstrated by skin testing (96, 97, 204), lymphoproliferation assays (91), or gamma interferon (IFN-γ) release assays (29, 86).

Table 1. Risk factors for IRIS

Genetic susceptibility (98)
Younger age (228, 231)
Male gender (250)
Unknown HIV infection (174)
Low CD4 T-cell count (mostly lower than 50 or 100/μl or %) before starting ART (96, 163, 178, 187, 228)
Higher CD8 T-cell % at baseline (228, 231)
High viral load before starting ART (96)
Lower hemoglobin level at baseline (231)
ART-naïve (250)
Advanced opportunistic disease, active and disseminated disease (35, 174, 187, 231)
High antigenic opportunistic burden (35, 178)
Boosted protease inhibitor in ART regimen (178)
More rapid initial decrease in viral load after starting ART (178, 208, 250)
Increase in CD4 T-cell count after starting ART (35, 187)
Short time interval between starting ART and inflammatory symptoms (32, 163, 174, 250)
Good adherence to ART (52)
Drug-resistant OI (low adherence to drugs for specific OIs)
Resource-limited setting
Immigration from a resource-limited country

Using an enzyme-linked immunospot assay, Bourgarit et al. demonstrated that the number of blood T cells responding to purified protein derivative (PPD) of tuberculin by producing IFN-γ increased in patients who developed "paradoxical" TB-IRIS after commencing ART (29). This did not occur in patients with treated TB infection who did not develop TB-IRIS after commencing ART. Furthermore, T-cell IFN-γ responses to CMV were similar in patients with and without TB-IRIS, indicating that the increased T-cell responses were specific to the pathogen that provoked the IRIS. Preliminary results from a prospective study of over 300 HIV-infected patients commencing ART in a country with a high prevalence of TB have demonstrated similar findings (86). In this study, a whole-blood IFN-γ release assay (Quantiferon-TB gold in-tube assay) was used to demonstrate that T-cell IFN-γ responses to PPD increased in patients who developed paradoxical or "unmasking" TB-IRIS. Similar findings were demonstrated by skin testing with PPD. Interestingly, both studies demonstrated that patients with paradoxical TB-IRIS had more T cells responding to PPD than T cells responding to secreted antigens of TB, such as ESAT-6 or CFP-10. These findings suggest that the T cells in patients with paradoxical TB-IRIS are responding to antigens expressed by nonreplicating *M. tuberculosis*. Further evidence that pathogen-specific T-cell responses are crucial in the immunopathogenesis of mycobacterial IRIS has been provided by the observation that IRIS can be provoked by mycobacteria that rarely cause disease, such as *Mycobacterium celatum* (17).

Mycobacterial IRIS is not always associated with an increase of the blood CD4 T-cell count. Phillips et al. (211) demonstrated that only about 10% of patients with NTM-IRIS did not have an increased CD4 T-cell count, while most studies of TB-IRIS patients have not shown such an association between TB-IRIS and increased CD4 T-cell counts (32, 35, 149, 163). There are several possible expla-

nations for this (94). First, the proportion of circulating mycobacteria-specific T cells may correlate poorly with the total CD4 T-cell count; second, mycobacteria-specific T cells might only be present in tissues; finally, restoration of cellular immune responses against mycobacterial antigens might primarily reflect improved function of other cells involved in antigen presentation and/or mycobacterial killing, such as dendritic cells and macrophages.

Immune restoration disease may be provoked by many pathogens other than mycobacteria (98). Although the immunopathogenesis of IRIS provoked by these pathogens has been less intensively studied, the evidence currently available supports a role for increased pathogen-specific immune responses. Thus, ART-associated hepatitis in HIV-infected patients with hepatitis C virus (HCV) coinfection is associated with increased serum levels of HCV-specific antibody (130, 260), CMV retinitis after ART is associated with increased serum levels of CMV-specific antibody (263), and CMV-specific CD8 T cells were clearly implicated in a case study of immune recovery uveitis complicating previous CMV retinitis (201). Furthermore, the atypical inflammatory response of progressive multifocal leukoencephalopathy (PML) after ART consists predominantly of CD8 T cells (190, 276), as might be expected for a cellular immune response against a viral pathogen.

The characteristics of pathogen-specific immune responses causing immunopathology in IRIS provoked by different pathogens are slowly becoming clearer. Evidence of T-cell activation in herpesvirus IRIS includes increased plasma levels of soluble CD30, a T-cell activation molecule belonging to the tumor necrosis factor (TNF) receptor family (263), and increased soluble CD26 (dipeptidyl peptidase IV) in patients with hepatitis caused by HCV IRIS (260). Genetic differences in killer immunoglobulin-like receptors may affect the regulation of cytotoxic T-cell and/or natural killer cell activation in IRIS provoked by herpesviruses (218).

There is also accumulating evidence that the immunopathology of IRIS involves cytokine production. Interleukin-12 (IL-12), a cytokine produced by antigen-presenting cells that induces Th1 immune responses, is increased in the ocular vitreous fluid of patients with immune recovery uveitis associated with previous CMV retinitis (240). Genetic studies also suggest that IL-12 affects the pathogenesis of IRIS provoked by herpesviruses, including CMV (217). Increased plasma levels of proinflammatory cytokines, including IL-6 and TNF, have been associated with IRIS provoked by various pathogens (29, 261, 262, 266). Of particular interest, preliminary data suggest that increased production of IL-6 and TNF might be associated with Kaposi's sarcoma presenting as immune restoration disease in patients who had increased vascular endothelial growth factor production before and after developing IRIS (266). Increased IL-6 production may persist for at least 4 years in patients with herpesvirus IRIS (261), and increased production of proinflammatory cytokines as a result of IRIS might contribute to the immune activation that persists in some patients responding to ART (5).

DIAGNOSTIC CRITERIA

There is at this time no agreement concerning a case definition for IRIS. This lack of a definition is a major obstacle to promoting quality research on IRIS (53,

98, 245, 247, 248). Risk factors for IRIS are summarized in Table 1 (98, 163, 198, 228, 231, 250). Most or all of the following features should be present before a diagnosis of IRIS can be considered (64, 75, 96, 98, 112, 159, 171, 198, 243, 246–248):

- The patient is HIV positive (most common with advanced disease).
- There is a positive virologic and immunological response to ART which includes a decrease in viral load and an increase in CD4 T-cell count and/or an increased pathogen-specific immune response, such as a cellular immune response to PPD in patients with mycobacterial IRIS (an increase in CD4 count is not seen in all patients).
- There are systemic or localized symptoms consistent with an inflammatory response (and an unexpected clinical course).
- There is a temporal association between ART initiation and the onset of the syndrome (within several days to a few months). IRIS can also be seen in patients switching from a failing ART regimen to an effective suppressive therapy or restarting ART after a treatment interruption.
- Treatment failure (due to poor adherence, drug malabsorption, or drug resistance), a drug hypersensitivity reaction, or an alternative opportunistic infection or malignancy has been ruled out.

The diagnosis of IRIS poses a challenge for clinicians, as there is no test that confirms the diagnosis. Diagnosis relies upon a consistent history and the exclusion of alternative diagnoses (see above) to explain clinical deterioration. In areas where drug-resistant infections are frequent, extra efforts must be made to exclude drug resistance as a cause for clinical deterioration before diagnosing IRIS.

The clinical features of IRIS are strongly related to the type and location of the associated OI (64, 75, 96, 98, 112, 159, 171, 198, 243, 246–248). However, a few generalizations can be made. IRIS can manifest as a more exuberant presentation of an OI or as an atypical presentation, such as a focal inflammatory process in an atypical location. Symptoms can be systemic or localized. Anatomically compartmentalized phenomena, such as lymphadenitis or brain lesions, are seen in IRIS (98, 171). Constitutional features, like fever, are frequently present (48). Cutaneous IRIS after initiation of ART, like herpes simplex, varicella-zoster, warts, mollusca, or folliculitis infections, are observed quite often (228). Most cases of IRIS can be expected to occur within the first few days to weeks of initiating therapy. Vigilance needs to be especially high during this period, but cases continue to occur even after 1 or more years of ART (96, 228, 247). IRIS can also occur in the setting of ongoing prophylactic therapy, such as with cotrimoxazole, fluconazole, ganciclovir, azithromycin, and isoniazid (211).

Because the spectrum of OIs differs between different regions of the world, it is likely that similar geographical variance will be observed for IRIS (248).

GENERAL CONCEPTS OF MANAGEMENT

The optimum management of IRIS is dependent on the awareness by health care providers of its existence. Recognition that IRIS is a manifestation of an inflammatory response rather than direct treatment failure is crucial in avoiding unnecessary modifications in therapy. The management of IRIS, though supportive care is generally all that is required, needs to be tailored to the specific scenario and consists of the following general concepts (64, 75, 96, 98, 112, 159, 171, 198, 243, 246–248):

- treatment of the underlying opportunistic infection (in order to decrease the antigenic load), if therapy is available
- continuation of the effective ART in the majority of cases (mild and moderate IRIS symptoms will resolve spontaneously over time)
- discontinuation of ART will mostly result in a prompt or gradual symptomatic improvement. Ongoing deterioration after discontinuation is also seen. Discontinuation is only indicated when there are life-threatening events or when there is a risk for permanent sequelae. ART interruption has to be considered as a great risk in immune-deficient patients.
- judicious use of anti-inflammatory agents (like corticosteroids)

Whether corticosteroids are indicated for less severe presentations remains to be determined. Most cases are self-limiting and only symptomatic treatment may be required. It is important to consider the potential adverse effects of corticosteroids, particularly in patients with advanced immunosuppression. These include herpesvirus infection reactivations and Kaposi's sarcoma (84, 85). In a Ugandan (not IRIS-related) study, the benefits of prednisolone therapy on immune activation and CD4 T-cell count did not outweigh the risks of adverse events in HIV-infected patients with CD4 counts above 200/μl (185). Corticosteroids may be indicated in moderate and severe IRIS associated with TB, NTM, and cryptococcosis (27, 149, 155, 174, 211). Nonsteroidal anti-inflammatory drugs were successfully used in the treatment of necrotic lymphadenopathies. Use of other anti-inflammatory agents, like thalidomide, pentoxifylline, and montelukast, has been reported, but too little is known to recommend these agents (88, 131, 172).

SPECIFIC CLINICAL MANIFESTATIONS AND THERAPY

A variety of manifestations of IRIS have been described (for examples, see Fig. 1 to 5, below), particularly in patients with infections caused by mycobacteria (TB), fungi *(Pneumocystis jiroveci* and *Cryptococcus neoformans)* and viruses (varicella-zoster, hepatitis B and C viruses, and CMV), but also by bacteria, protozoa, and

parasites (Table 2) (64, 75, 98, 198, 246). Moreover, a few miscellaneous syndromes (autoimmune, inflammatory, and malignant) may worsen or appear after initiation of ART.

IRIS Associated with Nonviable Infectious Antigens and Infections

We can differentiate two conditions among the infection-associated IRIS (98): first, the "paradoxical" type, in which after initiating appropriate antimicrobial treatment and subsequently ART an inflammatory worsening of an infectious condition is noticed as a reaction to a dead or dying pathogen (155).

Secondly, in contrast with the previously diagnosed and treated infection, we can differentiate the "unmasking" type of infectious IRIS, where an incubating opportunistic infection, unrecognized and thus not treated prior to ART, is unmasked after starting ART due to an immune reaction to replicating organisms (33, 129, 211). The reasons for why these infections were not recognized, prior to the start of ART, may have been the limited presence of clinical signs due to ineffective immune responses of the patient or because diagnostic tests were unavailable in resource-limited settings. ART causes in these advanced HIV-infected patients an early immune recovery and subsequently an unmasking of the infection.

Mycobacteria

IRIS associated with *M. tuberculosis:* TB-IRIS. TB is the most frequent opportunistic infection (58, 114) and leading cause of death (176, 227) in HIV-infected patients in the developing world. The incidence of TB in patients with advanced HIV in areas of sub-Saharan Africa is up to 30/100 person-years (284). This means that a substantial proportion of patients initiating ART in developing world cohorts do so while on TB treatment (up to 25%), with undiagnosed active TB, or with a history of previously treated TB (162). It is not surprising then that TB-IRIS is a frequent early complication of ART as treatment programs roll out in these settings (149, 159, 181). TB-IRIS may manifest as one of the two above-described syndromes. For example, patients with an established diagnosis of TB and on appropriate TB treatment when starting ART may manifest with a paradoxical deterioration after starting ART. This is termed paradoxical TB-IRIS. Patients who have unrecognized active TB when they commence ART may present with inflammatory and accelerated manifestations of TB during early immune recovery as a result of their active TB being unmasked by immune reconstitution. This is termed unmasking TB-IRIS. Immune-driven paradoxical reactions in patients on TB treatment have been described in HIV-uninfected patients (47, 111), patients restoring immunity after discontinuing immunosuppressive therapies (15, 116), and HIV-infected patients not on ART (204). However, Narita et al. documented that paradoxical reactions were more common in HIV-infected patients after starting ART (36%) compared with HIV-infected patients not on ART (7%) and HIV-uninfected patients (2%). In this study the timing of the paradoxical reaction was also more closely temporally related to ART initiation than TB treatment initiation (204). Breen et al. documented similar findings (32). Patients who are started on ART and are then diagnosed with TB also seem to be at high risk of paradoxical reactions (62 versus 30% in those who started ART after starting TB

Table 2. Published IRIS-associated syndromes

IRIS associated with infection or infectious antigen
- Bacteria
  - *Bartonella henselae* (2, 247)
  - *Chlamydia trachomatis* (206)
- Mycobacteria
  - Bacillus Calmette-Guérin (221, 251)
  - *Mycobacterium leprae* (59, 160, 165, 183, 212, 271)
  - *M. tuberculosis* (28, 32, 35, 65, 90, 96, 103, 107, 116, 117, 125, 127, 131, 149, 150, 154, 155, 161, 163, 178, 181, 187, 204, 205, 208, 223, 225, 228, 244, 247, 250, 281)
  - NTM infections (1, 8, 11, 14, 17, 70, 73, 74, 94, 97, 153, 155, 157, 158, 178, 200, 208, 211, 223, 228, 236, 247, 250, 278)
- Fungi
  - *C. neoformans* (20, 21, 24, 27, 36, 43, 50, 71, 105, 126, 142, 156, 167, 174, 178–180, 226, 245, 247, 250, 256, 257, 265, 269, 277, 285, 286)
  - *Candida albicans* (127, 178)
  - *Tinea corporis* (127, 274)
  - *Histoplasma capsulatum* (34, 74, 249)
  - *Penicillium marneffei* (108)
  - *P. jirovecii* (10, 62, 68, 148, 178, 211, 228, 247, 283)
  - *Aspergillus fumigatus* (237)
- Parasites
  - Schistosomiasis (72, 89, 124)
  - *Strongyloides* (37, 66, 141, 152, 267)
- Protozoa
  - *Cryptosporidium* spp. (214)
  - Leishmaniasis (3, 19, 25, 100, 128, 139, 215, 230)
  - Microsporidia (99)
  - *Toxoplasma gondii* (127, 264, 270)
- Viruses
  - BK virus (9, 279)
  - CMV (6, 14, 67, 74, 83, 96, 101, 105, 122, 123, 134-136, 147, 167, 178, 189, 222, 247, 259, 263)
  - Hepatitis B and C (14, 41, 48, 79, 127, 130, 137, 186, 194, 197, 228, 234, 288)
  - Herpes simplex (60, 93, 96, 127, 142, 168, 220, 228, 229, 247)
  - Varicella-zoster (4, 51, 78, 80, 96, 127, 168, 178, 182, 220, 228, 247)
  - Kaposi's sarcoma (8, 31, 42, 56, 61, 96, 113, 169, 178, 228, 247)
  - HIV (105, 151)
  - Human papillomavirus (106, 127, 139, 143, 210, 228)
  - Buschke-Loewenstein tumor (papillomavirus) (195)
  - JC virus (18, 49, 55, 81, 105, 127, 138, 178, 190, 235, 252, 276)
  - Parvovirus (119, 207)

Other IRIS-associated syndromes
- Folliculitis (30, 69, 196, 224, 258)

Other disorders of immune reconstitution
- Autoimmune disorders
  - Cerebral vasculitis (273)
  - Guillain-Barré syndrome (177, 213, 220)
  - Lupus-like disease (13, 38, 39, 44, 76)
  - Polymyositis (241)

Table 2. *Continued*

Relapsing polychondritis (77, 287)
Rheumatoid arthritis (16, 38)
Thyroid (Graves') disease (46, 63, 76, 102, 132, 144, 233, 242, 247, 280)
Immune-mediated inflammatory disorders
Dermatofibromata (7)
Dyshidrosis (54)
Foreign body reaction (87, 199, 253)
Lymphoid interstitial pneumonitis (118)
Sarcoidosis (26, 92, 98, 104, 110, 170, 175, 191, 203, 247, 268)
Peyronie's disease (232)
Photodermatitis (22)
Kawasaki syndrome (275)
Malignancies
Lymphoma (145, 178, 216)
Reactive hemophagocytosis (115)
Lung cancer (146)

treatment in one study), and it is possible that this is a manifestation of IRIS in these patients (33).

Patients who develop paradoxical TB-IRIS typically give a history of having improved on TB treatment prior to ART initiation. After starting ART they then develop recurrent, worsening, or new clinical or radiological manifestations of TB (155, 163). Common manifestations are a return of symptoms, fever, enlargement of nodes, and worsening radiographic pulmonary infiltrates (155) (Fig. 1). The latter occurs in up to 45% of patients starting ART while on TB treatment (90). The spectrum of manifestations of paradoxical TB-IRIS that have been described is presented in Table 3 and Fig. 2. Paradoxical TB-IRIS is frequently a multisystem disorder with the same patient presenting with two or more manifestations simultaneously or sequentially. The median interval from ART initiation to onset of IRIS is 1 to 4 weeks (32, 35, 187, 204, 208), but it has been reported after only 3 days on ART (208), and late cases of IRIS with an onset years after ART initiation have also been described (117, 208). In two studies the median duration of IRIS was reported to be 57 days (208) and 76 days (187), and in a third study the mean duration of fever was 20 days (204). Nodal involvement can be more protracted, and it lasted for a median of 195 days in one study (208). Cases of prolonged paradoxical IRIS, where manifestations have lasted for over a year, have also been reported (208) (Fig. 3).

The reported incidence varies from 8 to 43% among patients starting ART while on TB treatment (32, 35, 149, 163, 181, 187, 204, 250) (Table 4). Several risk factors for the development of paradoxical TB-IRIS have been highlighted: disseminated TB (32, 35, 181, 187, 281), shorter delay between commencing TB treatment and ART (32, 163, 205, 250), lower baseline $CD4^+$ lymphocyte count (96, 163, 187), higher baseline viral load (35), greater reduction in viral load on ART (204, 205, 208, 250), and greater increase in $CD4^+$ lymphocytes (35, 187) or CD4/CD8 ratio (35). A supportive investigation for the diagnosis of TB-IRIS is an upgrading of the tuberculin skin test following ART (204).

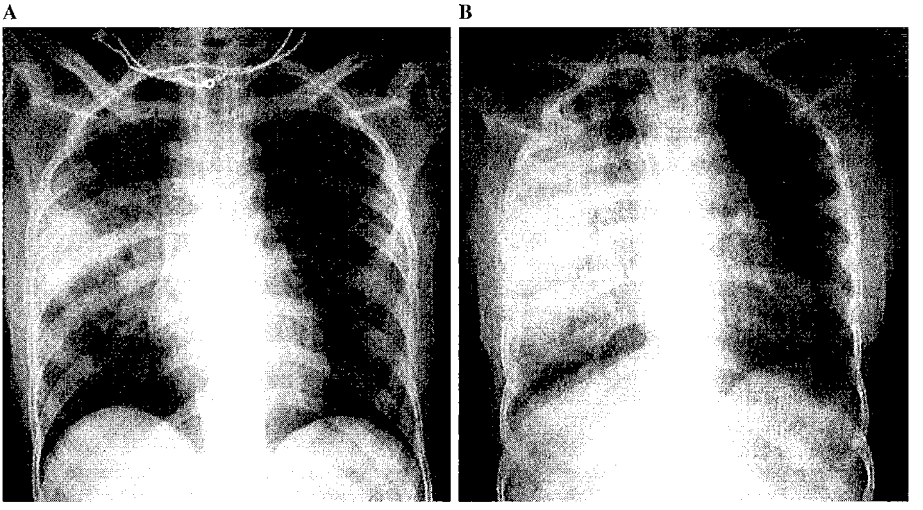

Figure 1. Paradoxical pulmonary TB-IRIS. In 2003, an 18-year-old Ghanaian woman was admitted because of cough for 3 months, persistent fever, and loss of more than 10% of body weight. A chest X-ray showed a right lobe pulmonary infiltrate (A). A bronchoalveolar lavage confirmed the diagnosis of *M. tuberculosis* infection. She was found to be HIV seropositive, and her $CD4^+$ lymphocyte count was 19 cells/μl. After 2 days of antituberculosis treatment the fever disappeared. She was started on efavirenz, lamivudine, and zidovudine. One week later she again developed high fever, and the pulmonary infiltrate had markedly increased (B). Moreover, she developed signs of polyarthritis of the hands, elbows, and knees. A puncture of an inflamed joint did not reveal any pathogen. She recovered finally with corticosteroid treatment and the continuation of the antituberculosis and antiretroviral treatment.

In a review of 86 TB-IRIS cases, management involved corticosteroids in 26%, ART interruption in 15%, surgery in 7%, and thalidomide and pentoxifylline in one patient each (155). Breen et al. reported that in eight patients with paradoxical TB-IRIS treated with corticosteroids because of severe systemic manifestations or prolonged duration (32), improvement occurred in all after a median of 3 days using doses of prednisone of 10 to 80 mg/day. However, no prospective studies regarding the management of paradoxical TB-IRIS have been conducted. Most clinicians would consider corticosteroids for the treatment of patients with more severe presentations, such as respiratory failure, vital structure compression, or central nervous system manifestations. A randomized placebo-controlled trial of prednisone for mild and moderate paradoxical TB-IRIS is under way in South Africa. Some clinicians have interrupted ART for severe manifestations (35). Surgical intervention may occasionally be required for complications such as organ rupture or for drainage procedures. Radiologically guided aspiration of cold abscesses has also been reported to be a beneficial therapeutic intervention (225).

Unmasking TB-IRIS is less well defined. Few cases have been described (33, 103, 129). Goldsack et al. reported a patient in whom subclinical TB was probably

Table 3. Range of paradoxical and unmasking TB-IRIS manifestations

Worsening or recurrence of TB symptoms
Weight loss
Fever
Systemic inflammatory response syndrome
Nodal enlargement with or without suppuration and sinus formation
Cold abscess formation
Respiratory manifestations
Progressive pulmonary infiltrates on chest radiography (several patterns described, including miliary infiltrates and alveolitis)
Pleural effusions
Pulmonary cyst formation
Nodal compression of airway
Respiratory failure
Abdominal manifestations
Hepatic enlargement and abscesses, cholestasis
Splenic enlargement, rupture, and abscesses
Intestinal involvement (ileocecal perforation reported)
Peritonitis
Ascites
Diarrhea
Psoas and intra-abdominal abscesses
Pancreatitis
Central nervous system manifestations
Tuberculoma enlargement
Meningitis
Genitourinary tract manifestations
Renal involvement with acute renal failure
Ureteric compression
Epipidymo-orchitis
Other system involvement
TB arthritis and osteitis
Serositis
Pericardial effusion
Skin lesions
Bone marrow involvement
Parotitis
Hypercalcemia

present prior to ART and who then 2 weeks after initiating ART developed bilateral miliary infiltrates complicated by acute respiratory distress syndrome attributed to TB-IRIS (103). Breen et al. (33) in a study conducted in the United Kingdom reported that the initiation of ART tended to amplify the frequency of presentations of TB: 13 of 19 patients who developed TB while receiving ART in this cohort did so early (median, 41 days after initiation of ART). It is important, however, that the term unmasking TB-IRIS not be used to refer to all patients who develop TB while receiving ART. In settings where TB is endemic, in particular, incident TB is frequent in patients on ART, particularly in the first 3 months (162, 244). Many of these cases cannot be regarded as IRIS, as they have typical TB presentations and reflect high rates of ongoing transmission and reactivation. Indeed,

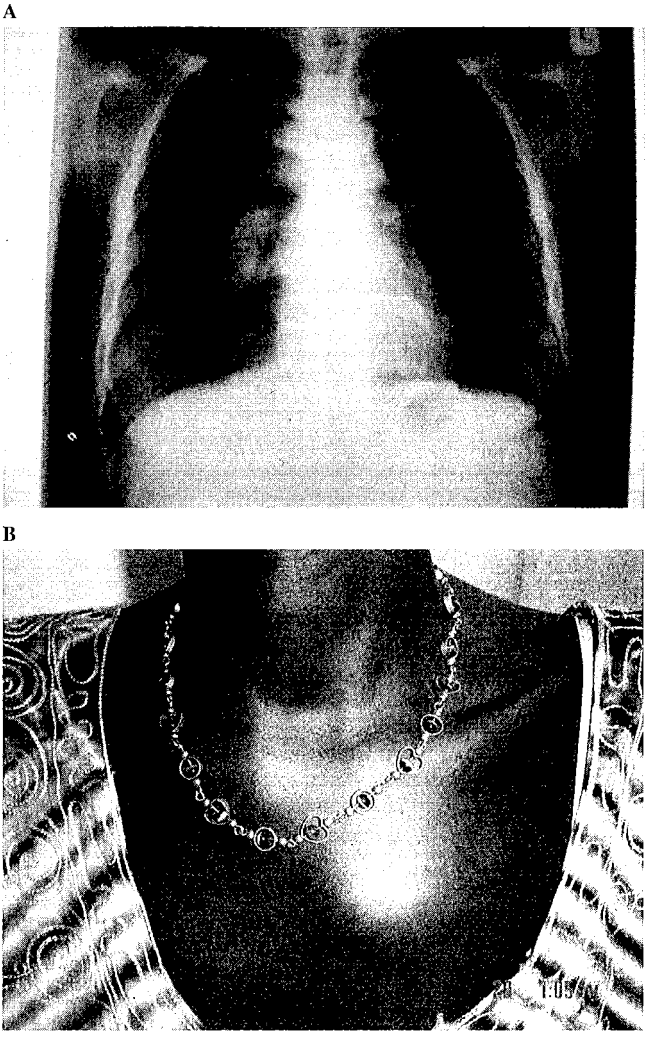

Figure 2. Paradoxical type of TB-IRIS with abscess formation. In August 2004, a Ugandan women with HIV infection was diagnosed with pulmonary *M. tuberculosis* infection. Her $CD4^+$ lymphocyte count was 9 cells/μl. Two weeks after the start of the antituberculosis treatment, antiretroviral treatment was started (zidovudine, lamivudine, and efavirenz). Four months later she presented with a swollen cervical lymph node, hilar lympadenopathy (A), and a thoracic wall tuberculous abscess (B). Aspiration of the lymph node showed the presence of acid-fast bacilli, but a culture was not performed.

many of these cases are probably occurring because of persistent immunodeficiency (159) rather than immune reconstitution. Further research to define what differentiates a patient with unmasking TB-IRIS from other cases of TB diagnosed in

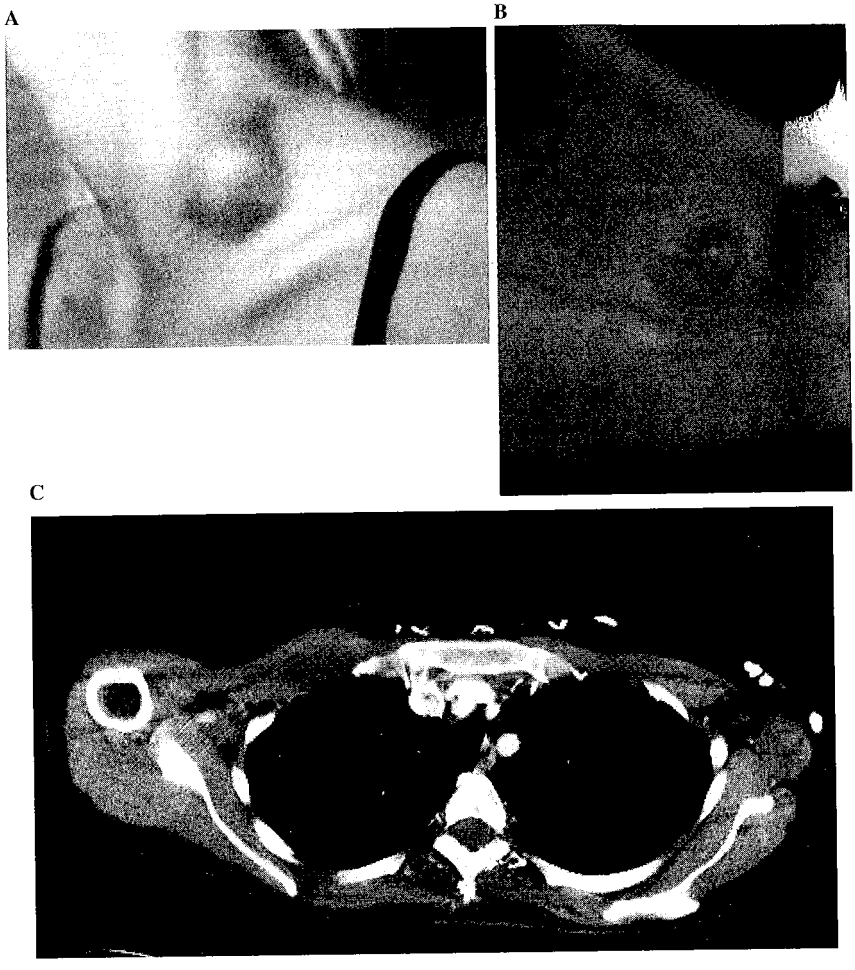

Figure 3. Recurrent paradoxical TB-IRIS. In 2000, a 32-year-old Caucasian woman with a $CD4^+$ lymphocyte count of 19 cells/μl was started on antituberculosis treatment because of disseminated tuberculosis. Her clinical condition initially improved, but 2 weeks after starting highly active ART she developed high fever, multiple inflammatory lymph nodes and abscesses (A), a pleural effusion, and ascites. Aspiration of an abscess revealed acid-fast bacilli and a positive *M. tuberculosis* culture. Over the next 9 months the abscesses and fever waxed and waned, usually responding temporarily to the administration of prednisone. They finally disappeared completely after 1 year of antituberculosis treatment (28). After 4 years on highly active ART she developed a cervical abscess (B) and a thoracic wall abscess (C) (the computed tomography scan shows a thoracic wall abscess similar to the abscess of the patient shown in Fig. 2). Her $CD4^+$ lymphocyte count was then 300 cells/μl. On aspiration of an abscess, only one acid-fast bacillus was found, and cultures remained negative. The abscesses finally disappeared after antituberculosis treatment (117).

Table 4. Paradoxical TB-IRIS: clinical case series that have reported on ≥8 patients with TB-IRIS

Author(s) (reference)	Country	Incidence of TB-IRIS (%)	Median or mean interval (days) from ART to IRIS	Significant association(s)[a]
Breen et al. (32)[b]	United Kingdom	29	11	Starting ART within 6 wk of TB diagnosis
Breton et al. (35)	France	43	12	Greater increase in CD4 % and CD4/CD8 ratio; disseminated TB
Kumarasamy et al. (149)	India	8	42	NR
Lawn et al. (154)	South Africa	12	14	Lower baseline CD4 count; shorter interval to starting ART
Manosuthi et al. (181)	Thailand	13	32	Extrapulmonary TB
Michailidis et al. (187)[c]	United Kingdom	26	15 (for those with paradoxical IRIS)	Lower baseline CD4 count; disseminated TB; greater CD4 rise on ART
Narita et al. (204)	United States	36	15	PPD conversion
Olalla et al. (208)[d]	Spain	27	18	Greater decrease in VL; lower CD4 count at 6 mo
Shelburne et al. (245)[e]	United States	30	46	Shorter interval to starting ART; more rapid initial fall in VL

[a] Abbreviations: NR, not reported; VL, viral load.
[b] Breen et al. reported 14 paradoxical reactions in 50 HIV-infected patients receiving TB treatment. Of the 50, 28 commenced ART after TB treatment, and 8 of these developed paradoxical TB-IRIS. Data shown are for these 8 patients.
[c] Fourteen IRIS cases were reported. Nine of these were paradoxical IRIS cases. Data shown are for all 14 cases.
[d] In the Olalla et al. study, eight of the nine cases were associated with TB; the other was associated with *M. avium* complex. Data shown are for all nine.
[e] This paper reported on 57 cases of TB, *M. avium* complex, and cryptococcal IRIS (26 of 57 were TB-IRIS). Five of these 57 patients started ART before the opportunistic infection was diagnosed and were thus not paradoxical IRIS cases. The data shown here relate to all 57 patients.

patients on ART who do not have IRIS, on the basis of clinical presentation and immunological parameters, is required.

It has been predicted that as ART programs roll out in regions where TB is endemic, large numbers of cases of undiagnosed TB will be unmasked by ART in this way, particularly because diagnostic capabilities that allow diagnosis prior to ART, such as bronchoscopy and TB culture, are very limited in these settings (129). Unmasking forms of IRIS might be prevented by thoroughly screening for opportunistic infections and commencing patients on appropriate OI treatment before ART initiation. Screening methods for TB prior to ART include clinical, radiological, and/or microbiological methods, although no particular strategy has been prospectively validated. A simple symptom screen used prior to isoniazid preventive therapy in HIV-infected patients has been shown to have a sensitivity of 100% for diagnosing TB (193), but no similar study prior to ART initiation has been con-

ducted. Whether routine chest radiology would increase the diagnostic yield is not known, but it is important to note that patients who develop unmasking TB-IRIS may have a normal baseline chest radiograph (103, 129). TB culture to screen prior to ART would be unavailable in many settings where TB is endemic, relatively expensive, and may delay ART initiation. Given that IRIS is more frequent in patients initiating ART with low CD4 counts (96, 187), initiation of ART prior to advanced immunosuppression would be expected to reduce the risk of all forms of IRIS.

IRIS associated with other mycobacterial infections. NTM-IRIS is characterized by a wide range of clinical presentations and severity (155). Paradoxical worsening and unmasking syndromes have both been reported, although the majority (75%) were due to unmasking of previous subclinical infection in a case series of 51 patients in a high-income country (211) (Fig. 4). Focal or diffuse lymph node enlargement is the most commonly described feature in the literature (in approximately 70% of the patients) (97, 98, 155, 211, 223). Constitutional, pulmonary, and abdominal symptoms and skin manifestations, presenting as an erythema nodosum, are also seen (14, 98, 155, 211, 247, 250). Draining sinuses, necrotic subcutaneous nodules, endobronchial nodules, small bowel involvement, peritonitis, osteomyelitis, cholestasis, Addison's disease, paravertebral abscess, cerebral infection, prostate abscess, parotitis, and hypercalcemia have been described (1, 11, 14,

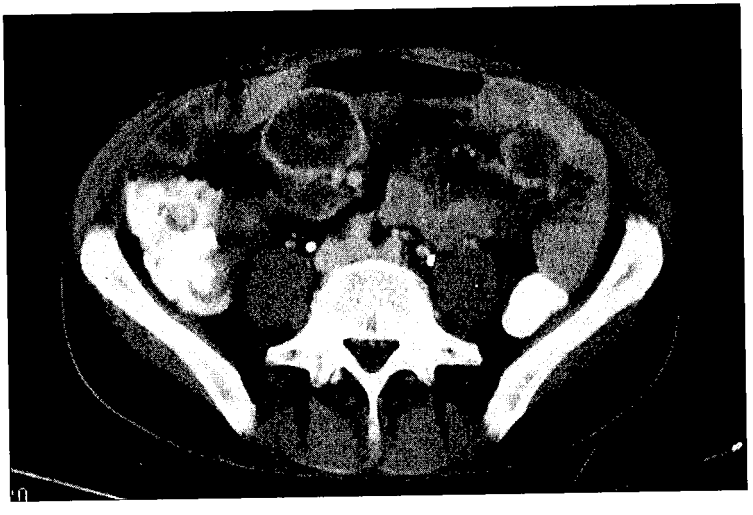

Figure 4. Unmasking *Mycobacterium avium* complex (MAC)-associated IRIS. In 1996, a 44-year-old Caucasian man, with a $CD4^+$ lymphocyte count of 17 cells/μl, was started on lamivudine, stavudine, saquinavir, and ritonavir. Four months later he was admitted to the hospital because of 2 months of abdominal pain and episodes of fever. His $CD4^+$ lymphocyte count was then 150 cells/μl. A computed tomography scan of the abdomen showed multiple intraabdominal hypodense multilocular structures (abscesses). During an exploratory laparotomy, biopsies and cultures were obtained. Cultures grew MAC. The patient recovered completely during highly active ART and MAC treatment.

70, 73, 74, 96, 155, 158, 200, 211, 247, 250, 278). The long-term prognosis is favorable for ART-adherent patients. Intra-abdominal disease is associated with greater morbidity than is peripheral lymphadenitis (211). Patients should be treated with antimycobacterial therapy. For moderate and severe disease, corticosteroids with a slow tapering of the dose (over weeks or months) may be considered (73). Suppurative lymphadenitis can be incised and drained but may result in chronic sinus formation. It also responds clinically to corticosteroids (73). Overall, mortality in the case series of Phillips et al. was 20%, but those authors did not report a direct attribution to the IRIS phenomenon (159). Leprosy-related IRIS presents usually with the unmasking of previous subclinical disease, manifesting with borderline and a type I reactional state (59, 160, 165, 183, 212, 271). Associated neuritis typically requires corticosteroid treatment (64). A recent report from Thailand described some cases of atypical unmasking manifestations of *Mycobacterium bovis* BCG-associated lymphadenitis and abscesses in children after recent BCG vaccination and then starting ART (221, 251).

Fungi

IRIS associated with *C. neoformans* infection. The most common manifestation of *C. neoformans*-associated IRIS is a sterile inflammatory clinical relapse after a successfully treated cryptococcal meningitis just after starting ART (paradoxical type) (156, 174, 245, 256). This usually manifests as recurrent meningitis. The inflammatory response, as judged by white blood cell counts in the cerebrospinal fluid (CSF), may be quite brisk, and also a high CSF protein level is commonly found, despite negative CSF cultures and declining *C. neoformans* CSF antigen titers (156, 174, 245) (Fig. 5). An unmasking type of cryptococcal IRIS with positive cultures has also been reported (156, 245, 285). The intracranial pressure may be markedly elevated, necessitating either repeated large-volume lumbar punctures or shunting procedures (50, 174, 245, 286). Intravenous amphotericin B deoxycholate is the therapy of choice for cryptococcal meningitis (21). On the basis of the results of the study of van der Horst et al., oral flucytosine in combination with amphotericin B is superior to amphotericin alone (272). High doses of fluconazole can be used in resource-limited settings, but only when amphotericin is unavailable: higher doses of fluconazole in combination with flucytosine should be investigated (173). The benefit of concomitant use of corticosteroids in cryptococcal IRIS is not proven, although a good clinical response has been reported in some cases (27, 142, 174, 247, 286). The time relation (2 to 8 weeks after starting ART), the paradoxical worsening of clinical symptoms (after successful treatment of the initial meningitis), and the laboratory tests of these cases of cryptococcal meningitis suggest that the clinical events are due to the immunologic changes associated with successful ART. Shelburne et al. found that 30% of patients who initiated ART developed a *Cryptococcus*-associated IRIS. In this cohort, 14 of 81 patients previously diagnosed with cryptococcal meningitis developed a paradoxical IRIS, 3 developed an unmasking IRIS meningitis, and 1 patient developed lymphadenitis. The majority of patients (61%) developed symptoms of IRIS within 30 days (245). However, Lortholary et al. describe in France 12 paradoxical IRIS cases in their retrospective study of 120 patients with cryptococcal meningitis. The

Figure 5. Paradoxical cryptococcus-associated IRIS. In 2002, a 26-year-old Caucasian man was hospitalized because of worsening headache and vomiting over a period of a few weeks. He was diagnosed as being HIV seropositive, with a $CD4^+$ lymphocyte count of 12 cells/μl and a viral load of >750,000 copies/ml. India ink staining of the CSF revealed *C. neoformans*. Visual acuity was normal. Treatment with amphotericin B and methylprednisolone (80 mg/day, intravenous) was started, together with lopinavir-ritonavir, lamivudine, and zidovudine. Initially his clinical condition improved, but after 2 weeks of amphotericin therapy the nausea and vomiting reappeared. The intracranial pressure was 45 mm Hg (normal is <21 mm Hg). Six weeks after admission he was discharged on oral fluconazole, lopinavir-ritonavir, lamivudine, zidovudine, methylprednisolone (16 mg daily), and acetazolamid. At that time, his CD4 lymphocyte count was 28 cells/μl and his HIV viral load was <400 copies/ml. Eight weeks later, he was readmitted with vomiting, anorexia, weight loss, and bilateral progressive visual loss. One week before readmission the methylprednisolone had been decreased to 8 mg daily. India ink examination of the CSF showed the presence of *C. neoformans*, but cultures remained negative. One week after the onset of his visual complaints, he experienced complete loss of vision. Fundoscopy showed bilateral papilledema. Magnetic resonance imaging of the brain revealed an effusion around the optic nerves. Surgical decompression of the right optic nerve was performed. Microscopic examination of the fluid obtained during surgery revealed *C. neoformans,* but a fungal culture of the fluid remained negative. Today he is in good general health, with a $CD4^+$ lymphocyte count of >400 cells/μl and a viral load of <50 copies/ml, but the bilateral blindness remains (71).

median time between start of ART and onset of IRIS was 8 months. Independent risk factors for IRIS were a new HIV diagnosis, a CD4 cell count lower than 10, fungemia at baseline, and initiation of ART within 2 months of cryptococcosis (174). Sungkanuparph et al. found in a Thai study that this syndrome is uncommon within the first 3 months of ART and may occur as late as 27 months after initiation (265). Drug failure due to fluconazole resistance is infrequent but may occur. Inadequate adherence to oral prophylactic treatment is a possible reason for drug failure causing an inadequately controlled fungal infection. It is also likely that

IRIS contributes to the presentation and re-presentation of some patients who are still culture positive (20). Other more peculiar and atypical presentations of *C. neoformans*-associated IRIS are described in the literature as presenting mostly at a later stage, like necrotizing mediastinal or cervical lymphadenitis, intracranial or intramedullary cryptococcomas, cerebellitis, necrotizing pneumonia, respiratory failure due to acute respiratory distress syndrome, recurrent cutaneous abscesses, and hypercalcemia (24, 36, 43, 126, 180, 269, 277).

IRIS associated with *P. jiroveci*. One to 3 weeks after initiating ART, some patients, previously treated for *P. jirovecii* pneumonia with antibiotics and corticosteroids and who responded well initially, may present with a paradoxical syndrome. Treatment with antipneumocystis therapy and corticosteroids then needs to be reinstated (10, 148, 283).

IRIS associated with *Histoplasma capsulatum*. Recently, histoplasmosis has been associated with IRIS in advanced HIV-infected patients (34). Cases present with the paradoxical or the unmasking type. Disseminated disease is the most common manifestation, with fever and skin lesions. Lymphadenitis, cerebral, pulmonary, and/or abdominal involvement may also be observed. Liver abscesses and granulomatous uveitis have also been reported (34, 249).

IRIS associated with parasites. Tropical infections, such as schistosomiasis, strongyloidiasis, cryptosporidiosis, and leishmaniasis, are being reported more frequently in association with IRIS (159). ART causes mainly the unmasking syndrome of the underlying tropical condition (164). Some paradoxical cases of IRIS have also been published (139). It is not yet clear whether such cases represent isolated clinical phenomena or whether these manifestations are indicative of an important burden of disease among patients accessing ART in resource-limited settings (163).

Viruses

IRIS associated with CMV. Eye disease is the most common presentation of CMV-IRIS (120–122). Paradoxical and unmasking CMV retinitis are two possible manifestations of IRIS and manifest early after initiation of ART (121). Patients improve rapidly after further continuation or initiation of anti-CMV therapy. Another CMV-related IRIS eye disease is vitritis (134, 135). Initially causing acute visual loss, this vitritis is ultimately benign. Preexisting CMV infection may rarely result in atypical CMV IRIS manifesting as submandibular inflammation, colitis, pneumonia, or pancreatitis. These manifestations are most commonly seen at a later stage (74, 101, 123, 189, 222).

In patients with treated and inactive CMV retinitis, an immune recovery uveitis, with important and sometimes permanent visual morbidity, is reported as a late phenomenon after starting ART (136). Uncontrolled studies of treatment for immune recovery uveitis with anti-CMV therapy or intraocular corticosteroids have not provided convincing evidence that either intervention is beneficial, although some have reported some efficacy (6, 67, 83, 147, 259).

IRIS associated with hepatitis B and C viruses. In a subset (1 to 5%) of hepatitis B or C virus-infected patients, an IRIS has been seen approximately 1 to 2 months after initiating ART. Patients have mostly elevated liver enzymes and

hepatitis viremia and are asymptomatic (41, 79, 130, 186, 234, 288). Some of them have symptoms of hepatitis, and this results occasionally in a fulminant hepatitis or, in the long term, cirrhosis (197, 288). These hepatitis phenomena are mostly self-limiting. ART seldom needs to be stopped because of hepatic impairment. Differential diagnoses with drug toxicity or other OIs are difficult and need further investigation.

IRIS associated with JC virus. The diagnosis of PML mitigates the urgent need to start ART (18, 49). About 20% of these patients develop a paradoxical worsening with new or worsening neurological symptoms (18, 49, 55, 138). Unmasking forms after the initiation of ART have been reported. After 1 to 2 months there is a spontaneous improvement in many cases. However, PML-associated IRIS may result directly or indirectly in a fatal outcome despite a good response to ART (235, 252).

IRIS associated with other viruses. Herpes simplex and varicella-zoster viruses are very common cutaneous IRIS phenomena (228). Couppie reported an up-to-fourfold increase in genital herpes in the period after ART initiation (60). Varicella-zoster virus infection occurred in a study two to nine times more often after initiating ART (4). Several prospective studies showed an incidence of 12, 8, and 7%, respectively, in varicella-zoster-related IRIS after introduction of ART (78, 80, 182). Such cases are almost always limited to a localized dermatomal distribution and respond well to acyclovir or famciclovir.

In a recent published cohort study, 78% of all IRIS events were due to dermatological IRIS: a genital herpesvirus infection (50%), a varicella-zoster virus infection (9%), molluscum contagiosum (9%), or genital warts (23%) (228). A useful review of dermatological manifestations was published last year (168). Existing condylomata and viral warts often flare up after initiating ART (96, 106, 143, 168). Most of the time the lesions taper after some time without treatment. Occlusive topical application of cidofovir is worth considering in the treatment of human papillomavirus-associated IRIS (140). Surgical removal of these lesions is sometimes necessary. Herpes simplex and varicella-zoster viruses have been associated with myelitis and encephalitis with moderate to severe outcome, and parvovirus B19 has been associated with focal encephalitis (51, 96, 207, 219). Recently, a case report of IRIS due to BK virus-associated meningoencephalitis showed clinical and radiographic improvement under ART (279).

There have been reports of patients developing Kaposi's sarcoma as an IRIS-like syndrome (31, 56, 169). Preexisting Kaposi's sarcoma lesions may worsen and have a rapid clinical progression. Despite an initial flare of Kaposi's sarcoma lesions, ART should be continued. Subcutaneous or systemic chemotherapy is effective (42, 113). Disseminated Kaposi's sarcoma IRIS is mostly associated with edema, can be life-threatening, and is probably underreported in resource-limited settings. Deaths related to Kaposi's sarcoma-IRIS have largely been due to pulmonary involvement (61, 169).

Other Immune Reconstitution-Associated Syndromes

New or worsening folliculitis is seen quite often after ART. Local antibacterial treatment with concomitant topical corticosteroids can help, but sometimes these lesions are therapy resistant (168, 196, 224).

Other Disorders of Immune Reconstitution

The following syndromes are very unusual, are based on case reports, and have a pathogenesis other than typical pathogen-associated IRIS.

Autoimmune Disorders

Graves' disease, systemic lupus erythematosus, and rheumatoid arthritis may present or become worse after the initiation of ART. Autoimmune disease can be recurrent and more aggressive and difficult to control due to ART (16, 38, 39, 46, 63, 76, 102, 132, 192). Graves' disease presents as a thyrotoxicosis and needs to be treated appropriately with antithyroid drugs, beta blockers, and/or thyroid ablation.

Immune-Mediated Inflammatory Disorders

Sarcoidosis after ART may manifest as pulmonary involvement, lymphadenopathy, or erythema nodosum or other cutaneous lesions. Paradoxical and unmasking forms have been reported. Corticosteroids are the treatment of choice (26, 104, 110, 170, 191, 203, 268).

CLINICAL OUTCOMES OF IRIS

The existing data suggest that the majority of patients who develop IRIS have good long-term clinical outcomes, partially due to the good immunological and viral response to ART (246, 248, 250). However, outcomes range from minimal morbidity to fatal progression. Mortality resulting from paradoxical TB-IRIS has been infrequently reported (155, 163, 181, 208), but a range of life-threatening complications have been described (155). These include acute renal failure (125), splenic rupture (35), intestinal perforation (107), respiratory failure (150), airway compression (35), and central nervous system involvement (208, 264). Central nervous system involvement with enlarging tuberculoma or TB meningitis likely carries the worst prognosis (198). In the era of ART, the long-term outcome of cryptococcosis has dramatically improved, although the short-term evolution is unchanged. Cryptococcosis-associated IRIS was associated with a high early mortality in a published South African study (21). From 18 patients started on ART, 6 developed a paradoxical and 3 an unmasking cryptococcal meningitis-associated IRIS; 5 and 1, respectively, died in each treated group (156). Early mortality in resource-limiting settings is probably higher than in resource-richer settings, due to the lack of proper health care services. Patients, mostly with advanced and disseminated disease (with a higher antigenic burden), consult generally at a later stage for community-based ART service (159). Although mortality due to IRIS has been infrequently reported in developing countries where expertise, investigation, and management options are limited, mortality may be underreported (159). The burdens to health care systems from this complex condition in terms of added investigations, management, and hospitalization have not been fully quantified, but they are likely to be substantial in settings where there is a high HIV prevalence. IRIS may also impact adherence to ART and TB treatment, although this has not been established.

PREVENTION

IRIS may be avoided by treating patients with a known OI with effective antimicrobial therapy for 1 or 2 months before initiation of ART. A time interval of shorter than 30 days was a risk factor in a retrospective study by Shelburne and colleagues (250). Antimicrobial therapy will reduce the microbial antigen burden and thus decreases the antigen stimulation to a reconstituting immune system and the risk for IRIS. Patients with CD4 T-cell counts lower than 100/μl are at high risk for developing IRIS and should be evaluated extensively (with directed history, physical examination, diagnostic testing, and rigorous follow-up), and these patients should be made aware of this potential complication before initiation of ART (159, 228). Battegay et al. recommend starting ART earlier in HIV disease progression prior to development of OIs (12). In patients with hepatitis B virus infection, it is recommended that treatment include tenofovir, lamivudine, or emtricitabine in triple therapy in order to simultaneously attain and maintain viral suppression of both infections (186).

Regarding the prevention of paradoxical TB-IRIS, given that a shorter interval between starting TB treatment and ART has been identified as a risk factor (32, 163, 205, 250), it is expected that delaying ART to the end of TB treatment would reduce the risk of TB-IRIS. However, the consequence of delaying ART initiation is likely to increase mortality (166). The mortality of patients with HIV-associated TB in developing countries who are not started on ART is substantial (202). Given that mortality from TB-IRIS is relatively rare, it has been argued that ART should thus not be delayed to prevent TB-IRIS in those with advanced immunosuppression (166). A modelling study suggested that if the mortality attributable to TB-IRIS were less than 4.6%, early ART initiation after TB treatment would be preferable (239). The World Health Organization recommends ART initiation 2 weeks to 2 months after TB treatment is started in patients with a CD4 count of <200 cells/μl but to delay ART initiation in patients with higher CD4 cell counts (282). Prospective studies to determine the optimal timing of ART introduction in patients with TB are under way (23).

CONCLUSIONS

ART has considerably improved the life expectancy of persons with HIV infection (82, 109, 184, 209). Antivirals, however, may also cause life-threatening complications, such as lactic acidosis, pancreatitis, hypersensitivity reactions, liver toxicity, and also IRIS.

Because of the wide variation in clinical presentations and associated etiologies of IRIS, a clinician should have a high index of suspicion for these syndromes, especially for TB-IRIS, NTM-IRIS, and cryptococcosis-associated IRIS (75, 159).

The fatality of IRIS is dependent on the awareness by health care providers of its existence. Recognition that IRIS is a manifestation of a poorly controlled inflammatory response rather than direct treatment failure is crucial for avoiding unnecessary modifications in therapy. The unmasking infective types of IRIS need to be treated with appropriate antimicrobials. The role of immunomodulators like

corticosteroids for moderate or severe IRIS is promising but needs to be studied prospectively in clinical trials.

REFERENCES

1. **Aberg, J. A., P. V. Chin-Hong, A. McCutchan, S. L. Koletar, and J. S. Currier.** 2002. Localized osteomyelitis due to Mycobacterium avium complex in patients with human immunodeficiency virus receiving highly active antiretroviral therapy. *Clin. Infect. Dis.* **35:**E8–E13.
2. **Abino, J. F., R. Peraldi, H. Lepidi, M. Luciani, and P. M. Girard.** 2002. Bacillary splenitis (Bartonella henselae) during immune restoration in an HIV-infected patient. *AIDS* **16:**1429–1430.
3. **Albrecht, H.** 1998. Leishmaniosis—new perspectives on an underappreciated opportunistic infection. *AIDS* **12:**2225–2226.
4. **Aldeen, T., P. Hay, F. Davidson, and R. Lau.** 1998. Herpes zoster infection in HIV-seropositive patients associated with highly active antiretroviral therapy. *AIDS* **12:**1719–1720.
5. **Almeida, C. A., P. Price, and M. A. French.** 2002. Immune activation in patients infected with HIV type 1 and maintaining suppression of viral replication by highly active antiretroviral therapy. *AIDS Res. Hum. Retrovir.* **18:**1351–1355.
6. **Arevalo, J. F., A. J. Mendoza, and Y. Ferretti.** 2003. Immune recovery uveitis in AIDS patients with cytomegalovirus retinitis treated with highly active antiretroviral therapy in Venezuela. *Retina* **23:**495–502.
7. **Bachmeyer, C., F. Cordier, L. Blum, A. Cazier, O. Verola, and S. Aractingi.** 2000. Multiple eruptive dermatofibromas after highly active antiretroviral therapy. *Br. J. Dermatol.* **143:**1336–1337.
8. **Ball, S. C.** 2005. Immune reconstitution in several forms. *AIDS Read.* **15:**17–20.
9. **Barouch, D. H., W. C. Faquin, Y. Chen, I. J. Koralnik, G. K. Robbins, and B. T. Davis.** 2002. BK virus-associated hemorrhagic cystitis in a human immunodeficiency virus-infected patient. *Clin. Infect. Dis.* **35:**326–329.
10. **Barry, S. M., M. C. Lipman, A. R. Deery, M. A. Johnson, and G. Janossy.** 2002. Immune reconstitution pneumonitis following Pneumocystis carinii pneumonia in HIV-infected subjects. *HIV Med.* **3:**207–211.
11. **Bartley, P. B., A. M. Allworth, and D. P. Eisen.** 1999. Mycobacterium avium complex causing endobronchial disease in AIDS patients after partial immune restoration. *Int. J. Tuberc. Lung Dis.* **3:**1132–1136.
12. **Battegay, M., R. Nuesch, B. Hirschel, and G. R. Kaufmann.** 2006. Immunological recovery and antiretroviral therapy in HIV-1 infection. *Lancet Infect. Dis.* **6:**280–287.
13. **Behrens, G., C. Knuth, I. Schedel, M. Mendila, and R. E. Schmidt.** 1998. Highly active antiretroviral therapy. *Lancet* **351:**1057–1058.
14. **Behrens, G. M., D. Meyer, M. Stoll, and R. E. Schmidt.** 2000. Immune reconstitution syndromes in human immuno-deficiency virus infection following effective antiretroviral therapy. *Immunobiology* **202:**186–193.
15. **Belknap, R., R. Reves, and W. Burman.** 2005. Immune reconstitution to Mycobacterium tuberculosis after discontinuing infliximab. *Int. J. Tuberc. Lung Dis.* **9:**1057–1058.
16. **Bell, C., M. Nelson, and S. Kaye.** 2002. A case of immune reconstitution rheumatoid arthritis. *Int. J. STD AIDS* **13:**580–581.
17. **Bell, H. C., C. H. Heath, and M. A. French.** 2005. Pulmonary Mycobacterium celatum immune restoration disease: immunopathology and response to corticosteroid therapy. *AIDS* **19:**2047–2049.
18. **Berenguer, J., P. Miralles, J. Arrizabalaga, E. Ribera, F. Dronda, J. Baraia-Etxaburu, P. Domingo, M. Marquez, F. J. Rodriguez-Arrondo, F. Laguna, R. Rubio, R. J. Lacruz, J. Mallolas, V. de Miguel, et al.** 2003. Clinical course and prognostic factors of progressive multifocal leukoencephalopathy in patients treated with highly active antiretroviral therapy. *Clin. Infect. Dis.* **36:**1047–1052.
19. **Berry, A., B. Abraham, J. Dereure, V. Pinzani, P. Bastien, and J. Reynes.** 2004. Two case reports of symptomatic visceral leishmaniasis in AIDS patients concomitant with immune reconstitution due to antiretroviral therapy. *Scand. J. Infect. Dis.* **36:**225–227.

20. **Bicanic, T., T. Harrison, A. Niepieklo, N. Dyakopu, and G. Meintjes.** 2006. Symptomatic relapse of HIV-associated cryptococcal meningitis after initial fluconazole monotherapy: the role of fluconazole resistance and immune reconstitution. *Clin. Infect. Dis.* **43:**1069–1073.
21. **Bicanic, T., G. Meintjes, R. Wood, M. Hayes, K. Rebe, L. G. Bekker, and T. Harrison**. 2007. Fungal burden, early fungicidal activity, and outcome in cryptococcal meningitis in antiretroviral-naive or antiretroviral-experienced patients treated with amphotericin B or fluconazole. *Clin. Infect. Dis.* **45:**76–80.
22. **Bilu, D., A. J. Mamelak, R. H. Nguyen, P. C. Queiroz, J. Kowalski, W. L. Morison, and C. R. Martins.** 2004. Clinical and epidemiologic characterization of photosensitivity in HIV-positive individuals. *Photodermatol. Photoimmunol. Photomed.* **20:**175–183.
23. **Blanc, F. X., D. V. Havlir, P. C. Onyebujoh, S. Thim, A. E. Goldfeld, and J. F. Delfraissy.** 2007. Treatment strategies for HIV-infected patients with tuberculosis: ongoing and planned clinical trials. *J. Infect. Dis.* **196**(Suppl. 1)**:**S46–S51.
24. **Blanche, P., B. Gombert, C. Ginsburg, A. Passeron, I. Stubei, A. Rigolet, D. Salmon, and D. Sicard.** 1998. HIV combination therapy: immune restitution causing cryptococcal lymphadenitis dramatically improved by anti-inflammatory therapy. *Scand. J. Infect. Dis.* **30:**615–616.
25. **Blanche, P., B. Gombert, O. Rivoal, S. Abad, D. Salmon, and A. Brezin.** 2002. Uveitis due to Leishmania major as part of HAART-induced immune restitution syndrome in a patient with AIDS. *Clin. Infect. Dis.* **34:**1279–1280.
26. **Blanche, P., A. Passeron, B. Gombert, C. Ginsburg, D. Salmon, and D. Sicard.** 1999. Sarcoidosis and HIV infection: influence of highly active antiretroviral therapy. *Br. J. Dermatol.* **140:**1185.
27. **Boelaert, J. R., K. H. Goddeeris, L. J. Vanopdenbosch, and J. W. Casselman**. 2004. Relapsing meningitis caused by persistent cryptococcal antigens and immune reconstitution after the initiation of highly active antiretroviral therapy. *AIDS* **18:**1223–1224.
28. **Bottieau, E., A. Noe, E. Florence, B. Ostyn, and R. Colebunders**. 2002. Development of multiple abscesses in an HIV/TB co-infected patient after initiation of antituberculous and highly active antiretroviral therapy. *Acta Clin. Belg.* **57:**219–222.
29. **Bourgarit, A., G. Carcelain, V. Martinez, C. Lascoux, V. Delcey, B. Gicquel, E. Vicaut, P. H. Lagrange, D. Sereni, and B. Autran.** 2006. Explosion of tuberculin-specific Th1-responses induces immune restoration syndrome in tuberculosis and HIV co-infected patients. *AIDS* **20:**F1–F7.
30. **Bouscarat, F., E. Maubec, S. Matheron, and V. Descamps.** 2000. Immune recovery inflammatory folliculitis. *AIDS* **14:**617–618.
31. **Bower, M., M. Nelson, A. M. Young, C. Thirlwell, T. Newsom-Davis, S. Mandalia, T. Dhillon, P. Holmes, B. G. Gazzard, and J. Stebbing.** 2005. Immune reconstitution inflammatory syndrome associated with Kaposi's sarcoma. *J. Clin Oncol.* **23:**5224–5228.
32. **Breen, R. A., C. J. Smith, H. Bettinson, S. Dart, B. Bannister, M. A. Johnson, and M. C. Lipman.** 2004. Paradoxical reactions during tuberculosis treatment in patients with and without HIV co-infection. *Thorax* **59:**704–707.
33. **Breen, R. A., C. J. Smith, I. Cropley, M. A. Johnson, and M. C. Lipman.** 2005. Does immune reconstitution syndrome promote active tuberculosis in patients receiving highly active antiretroviral therapy? *AIDS* **19:**1201–1206.
34. **Breton, G., H. Adle-Biassette, A. Therby, J. Ramanoelina, L. Choudat, F. Bissuel, M. Huerre, F. Dromer, B. Dupont, and O. Lortholary.** 2006. Immune reconstitution inflammatory syndrome in HIV-infected patients with disseminated histoplasmosis. *AIDS* **20:**119–121.
35. **Breton, G., X. Duval, C. Estellat, X. Poaletti, D. Bonnet, M. D. Mvondo, P. Longuet, C. Leport, and J. L. Vilde.** 2004. Determinants of immune reconstitution inflammatory syndrome in HIV type 1-infected patients with tuberculosis after initiation of antiretroviral therapy. *Clin. Infect. Dis.* **39:** 1709–1712.
36. **Breton, G., D. Seilhean, P. Cherin, S. Herson, and O. Benveniste.** 2002. Paradoxical intracranial cryptococcoma in a human immunodeficiency virus-infected man being treated with combination antiretroviral therapy. *Am. J. Med.* **113:**155–157.
37. **Brown, M., J. D. Cartledge, and R. F. Miller.** 2006. Dissemination of Strongyloides stercoralis as an immune restoration phenomenon in an HIV-1-infected man on antiretroviral therapy. *Int. J. STD AIDS* **17:**560–561.

38. **Calabrese, L. H., E. Kirchner, and R. Shrestha.** 2005. Rheumatic complications of human immunodeficiency virus infection in the era of highly active antiretroviral therapy: emergence of a new syndrome of immune reconstitution and changing patterns of disease. *Semin. Arthritis Rheum.* **35:** 166–174.
39. **Calza, L., R. Manfredi, V. Colangeli, A. D'Antuono, B. Passarini, and F. Chiodo.** 2003. Systemic and discoid lupus erythematosus in HIV-infected patients treated with highly active antiretroviral therapy. *Int. J. STD AIDS* **14:**356–359.
40. **Campbell, I. A., and A. J. Dyson.** 1977. Lymph node tuberculosis: a comparison of various methods of treatment. *Tubercle* **58:**171–179.
41. **Carr, A., and D. A. Cooper.** 1997. Restoration of immunity to chronic hepatitis B infection in HIV-infected patient on protease inhibitor. *Lancet* **349:**995–996.
42. **Cattelan, A. M., M. L. Calabro, A. De Rossi, S. M. Aversa, M. Barbierato, M. Trevenzoli, P. Gasperini, M. Zanchetta, P. Cadrobbi, S. Monfardini, and L. Chieco-Bianchi.** 2005. Long-term clinical outcome of AIDS-related Kaposi's sarcoma during highly active antiretroviral therapy. *Int. J. Oncol.* **27:**779–785.
43. **Cattelan, A. M., M. Trevenzoli, L. Sasset, M. Lanzafame, U. Marchioro, and F. Meneghetti.** 2004. Multiple cerebral cryptococcomas associated with immune reconstitution in HIV-1 infection. *AIDS* **18:**349–351.
44. **Chamberlain, A. J., K. Hollowood, R. J. Turner, and I. Byren.** 2004. Tumid lupus erythematosus occurring following highly active antiretroviral therapy for HIV infection: a manifestation of immune restoration. *J. Am. Acad. Dermatol.* **51:**S161–S165.
45. **Chambers, S. T., W. A. Hendrickse, C. Record, P. Rudge, and H. Smith.** 1984. Paradoxical expansion of intracranial tuberculomas during chemotherapy. *Lancet* **2:**181–184.
46. **Chen, F., S. L. Day, R. A. Metcalfe, G. Sethi, M. S. Kapembwa, M. G. Brook, D. Churchill, A. de Ruiter, S. Robinson, C. J. Lacey, and A. P. Weetman.** 2005. Characteristics of autoimmune thyroid disease occurring as a late complication of immune reconstitution in patients with advanced human immunodeficiency virus (HIV) disease. *Medicine* (Baltimore) **84:**98–106.
47. **Cheng, V. C., P. L. Ho, R. A. Lee, K. S. Chan, K. K. Chan, P. C. Woo, S. K. Lau, and K. Y. Yuen.** 2002. Clinical spectrum of paradoxical deterioration during antituberculosis therapy in non-HIV-infected patients. *Eur. J. Clin. Microbiol. Infect. Dis.* **21:**803–809.
48. **Cheng, V. C., K. Y. Yuen, W. M. Chan, S. S. Wong, E. S. Ma, and R. M. Chan.** 2000. Immunorestitution disease involving the innate and adaptive response. *Clin. Infect. Dis.* **30:**882–892.
49. **Cinque, P., S. Bossolasco, A. M. Brambilla, A. Boschini, C. Mussini, C. Pierotti, A. Campi, S. Casari, D. Bertelli, M. Mena, and A. Lazzarin.** 2003. The effect of highly active antiretroviral therapy-induced immune reconstitution on development and outcome of progressive multifocal leukoencephalopathy: study of 43 cases with review of the literature. *J. Neurovirol.* **9**(Suppl. 1)**:**73–80.
50. **Cinti, S. K., W. S. Armstrong, and C. A. Kauffman.** 2001. Case report. Recurrence of increased intracranial pressure with antiretroviral therapy in an AIDS patient with cryptococcal meningitis. *Mycoses* **44:**497–501.
51. **Clark, B. M., R. G. Krueger, P. Price, and M. A. French.** 2004. Compartmentalization of the immune response in varicella zoster virus immune restoration disease causing transverse myelitis. *AIDS* **18:**1218–1221.
52. **Coetzee, D., A. Boulle, K. Hildebrand, V. Asselman, G. Van Cutsem, and E. Goemaere.** 2004. Promoting adherence to antiretroviral therapy: the experience from a primary care setting in Khayelitsha, South Africa. *AIDS* **18**(Suppl. 3)**:**S27–S31.
53. **Colebunders, R., L. John, V. Huyst, A. Kambugu, F. Scano, and L. Lynen.** 2006. Tuberculosis immune reconstitution inflammatory syndrome in countries with limited resources. *Int. J. Tuberc. Lung Dis.* **10:**946–953.
54. **Colebunders, R., M. Zolfo, and L. Lynen.** 2005. Severe dyshidrosis in two patients with HIV infection shortly after starting highly active antiretroviral treatment. *Dermatol. Online J.* **11:**31.
55. **Collazos, J., J. Mayo, E. Martinez, and M. S. Blanco.** 1999. Contrast-enhancing progressive multifocal leukoencephalopathy as an immune reconstitution event in AIDS patients. *AIDS* **13:**1426–1428.
56. **Connick, E., M. A. Kane, I. E. White, J. Ryder, and T. B. Campbell.** 2004. Immune reconstitution inflammatory syndrome associated with Kaposi sarcoma during potent antiretroviral therapy. *Clin. Infect. Dis.* **39:**1852–1855.

57. **Cooney, E. L.** 2002. Clinical indicators of immune restoration following highly active antiretroviral therapy. *Clin. Infect. Dis.* **34:**224–233.
58. **Corbett, E. L., C. J. Watt, N. Walker, D. Maher, B. G. Williams, M. C. Raviglione, and C. Dye.** 2003. The growing burden of tuberculosis: global trends and interactions with the HIV epidemic. *Arch. Intern. Med.* **163:**1009–1021.
59. **Couppie, P., S. Abel, H. Voinchet, M. Roussel, R. Helenon, M. Huerre, D. Sainte-Marie, and A. Cabie.** 2004. Immune reconstitution inflammatory syndrome associated with HIV and leprosy. *Arch. Dermatol.* **140:**997–1000.
60. **Couppie, P., F. Sarazin, E. Clyti, M. El Guedj, T. Vaz, D. Sainte-Marie, C. Marty, and M. Nacher.** 2006. Increased incidence of genital herpes after HAART initiation: a frequent presentation of immune reconstitution inflammatory syndrome (IRIS) in HIV-infected patients. *AIDS Patient Care STDs* **20:**143–145.
61. **Crane, H. M., H. Deubner, J. C. Huang, P. E. Swanson, and R. D. Harrington.** 2005. Fatal Kaposi's sarcoma-associated immune reconstitution following HAART initiation. *Int. J. STD AIDS* **16:**80–83.
62. **Crothers, K., and L. Huang.** 2003. Recurrence of Pneumocystis carinii pneumonia in an HIV-infected patient: apparent selective immune reconstitution after initiation of antiretroviral therapy. *HIV Med.* **4:**346–349.
63. **Crum, N. F., A. Ganesan, S. T. Johns, and M. R. Wallace.** 2006. Graves disease: an increasingly recognized immune reconstitution syndrome. *AIDS* **20:**466–469.
64. **Crum-Cianflone, N. F.** 2006. Immune reconstitution inflammatory syndromes: what's new? *AIDS Read.* **16:**199–217.
65. **Crump, J. A., M. J. Tyrer, S. J. Lloyd-Owen, L. Y. Han, M. C. Lipman, and M. A. Johnson.** 1998. Military tuberculosis with paradoxical expansion of intracranial tuberculomas complicating human immunodeficiency virus infection in a patient receiving highly active antiretroviral therapy. *Clin. Infect. Dis.* **26:**1008–1009.
66. **Currie, B. J., and J. S. McCarthy.** 2005. Strongyloides stercoralis infection as a manifestation of immune restoration syndrome? *Clin. Infect. Dis.* **40:**635.
67. **Dalessandro, L., and E. Bottaro.** 2002. Reactivation of CMV retinitis after treatment with subtenon corticosteroids for immune recovery uveitis in a patient with AIDS. *Scand. J. Infect. Dis.* **34:**780–782.
68. **Dean, G. L., D. I. Williams, D. R. Churchill, and M. J. Fisher.** 2002. Transient clinical deterioration in HIV patients with Pneumocystis carinii pneumonia after starting highly active antiretroviral therapy: another case of immune restoration inflammatory syndrome. *Am. J. Respir. Crit. Care Med.* **165:**1670.
69. **Delfos, N. M., A. F. Collen, and F. P. Kroon.** 2004. Demodex folliculitis: a skin manifestation of immune reconstitution disease. *AIDS* **18:**701–702.
70. **del Giudice, P., J. Durant, E. Counillon, V. Mondain, E. Bernard, P. M. Roger, and P. Dellamonica.** 1999. Mycobacterial cutaneous manifestations: a new sign of immune restoration syndrome in patients with acquired immunodeficiency syndrome. *Arch. Dermatol.* **135:**1129–1130.
71. **De Schacht, C., R. M. Smets, S. Callens, and R. Colebunders.** 2005. Bilateral blindness after starting highly active antiretroviral treatment in a patient with HIV infection and cryptococcal meningitis. *Acta Clin. Belg.* **60:**10–12.
72. **de Silva, S., J. Walsh, and M. Brown.** 2006. Symptomatic Schistosoma mansoni infection as an immune restoration phenomenon in a patient receiving antiretroviral therapy. *Clin. Infect. Dis.* **42:**303–304.
73. **Desimone, J. A., Jr., T. J. Babinchak, K. R. Kaulback, and R. J. Pomerantz.** 2003. Treatment of Mycobacterium avium complex immune reconstitution disease in HIV-1-infected individuals. *AIDS Patient Care STDs* **17:**617–622.
74. **DeSimone, J. A., R. J. Pomerantz, and T. J. Babinchak.** 2000. Inflammatory reactions in HIV-1-infected persons after initiation of highly active antiretroviral therapy. *Ann. Intern. Med.* **133:**447–454.
75. **Dhasmana, D. J., K. Dheda, P. Ravn, R. J. Wilkinson, and G. Meintjes.** 2008. Immune reconstitution inflammatory syndrome in HIV-infected patients receiving antiretroviral therapy: pathogenesis, clinical manifestations and management. *Drugs* **68:**191–208.

76. **Diri, E., P. E. Lipsky, and R. E. Berggren.** 2000. Emergence of systemic lupus erythematosus after initiation of highly active antiretroviral therapy for human immunodeficiency virus infection. *J. Rheumatol.* **27:**2711–2714.
77. **Dolev, J. C., T. A. Maurer, S. G. Reddy, L. E. Ramirez, and T. Berger.** 2004. Relapsing polychondritis in HIV-infected patients: a report of two cases. *J. Am. Acad. Dermatol.* **51:**1023–1025.
78. **Domingo, P., O. H. Torres, J. Ris, and G. Vazquez.** 2001. Herpes zoster as an immune reconstitution disease after initiation of combination antiretroviral therapy in patients with human immunodeficiency virus type-1 infection. *Am. J. Med.* **110:**605–609.
79. **Drake, A., A. Mijch, and J. Sasadeusz.** 2004. Immune reconstitution hepatitis in HIV and hepatitis B coinfection, despite lamivudine therapy as part of HAART. *Clin. Infect. Dis.* **39:**129–132.
80. **Dunic, I., O. Djurkovic-Djakovic, S. Vesic, S. Zerjav, and D. Jevtovic.** 2005. Herpes zoster as an immune restoration disease in AIDS patients during therapy including protease inhibitors. *Int. J. STD AIDS* **16:**475–478.
81. **Du Pasquier, R. A., and I. J. Koralnik.** 2003. Inflammatory reaction in progressive multifocal leukoencephalopathy: harmful or beneficial? *J. Neurovirol.* **9**(Suppl. 1)**:**2–31.
82. **Egger, M., M. May, G. Chene, A. N. Phillips, B. Ledergerber, F. Dabis, D. Costagliola, M. A. D'Arminio, F. de Wolf, P. Reiss, J. D. Lundgren, A. C. Justice, S. Staszewski, C. Leport, R. S. Hogg, C. A. Sabin, M. J. Gill, B. Salzberger, and J. A. Sterne.** 2002. Prognosis of HIV-1-infected patients starting highly active antiretroviral therapy: a collaborative analysis of prospective studies. *Lancet* **360:**119–129.
83. **El Bradey, M. H., L. Cheng, M. K. Song, F. J. Torriani, and W. R. Freeman.** 2004. Long-term results of treatment of macular complications in eyes with immune recovery uveitis using a graded treatment approach. *Retina* **24:**376–382.
84. **Elliott, A. M., B. Halwiindi, A. Bagshawe, R. J. Hayes, N. Luo, J. O. Pobee, and K. P. McAdam.** 1992. Use of prednisolone in the treatment of HIV-positive tuberculosis patients. *Q. J. Med.* **85:** 855–860.
85. **Elliott, A. M., H. Luzze, M. A. Quigley, J. S. Nakiyingi, S. Kyaligonza, P. B. Namujju, C. Ducar, J. J. Ellner, J. A. Whitworth, R. Mugerwa, J. L. Johnson, and A. Okwera.** 2004. A randomized, double-blind, placebo-controlled trial of the use of prednisolone as an adjunct to treatment in HIV-1-associated pleural tuberculosis. *J. Infect. Dis.* **190:**869–878.
86. **Elliott, J. H., S. Sarun, S. Chin, D. Chan, S. Chel, S. Huffam, R. Oelrichs, C. Hun, S. Pouv, K. H. Teng, V. Saphonn, J. Kaldor, D. Cooper, M. French, and C. V. Mean.** 2007. Tuberculosis-associated immune restoration disease is associated with increased PPD-specific T-cell responses detected by a whole blood interferon-γ release assay, abstr. MOAB101. *4th IAS Conf. HIV Pathog. Treat. Prev.,* 22 to 25 July 2007, Sydney, Australia.
87. **Farrant, P., and E. Higgins.** 2004. A granulomatous response to tribal medicine as a feature of the immune reconstitution syndrome. *Clin. Exp. Dermatol.* **29:**366–368.
88. **Fernandes, G. C., M. A. Vieira, M. C. Lourenco, A. J. Gadelha, L. C. Coura, and V. C. Rolla.** 2002. Inflammatory paradoxical reaction occurring in tuberculosis patients treated with HAART and rifampicin. *Rev. Inst. Med. Trop. Sao Paulo* **44:**113–114.
89. **Fernando, R., and R. Miller.** 2002. Immune reconstitution eosinophilia due to schistosomiasis. *Sex. Transm. Infect.* **78:**76.
90. **Fishman, J. E., E. Saraf-Lavi, M. Narita, E. S. Hollender, R. Ramsinghani, and D. Ashkin.** 2000. Pulmonary tuberculosis in AIDS patients: transient chest radiographic worsening after initiation of antiretroviral therapy. *Am. J. Roentgenol.* **174:**43–49.
91. **Foudraine, N. A., E. Hovenkamp, D. W. Notermans, P. L. Meenhorst, M. R. Klein, J. M. Lange, F. Miedema, and P. Reiss.** 1999. Immunopathology as a result of highly active antiretroviral therapy in HIV-1-infected patients. *AIDS* **13:**177–184.
92. **Foulon, G., M. Wislez, J. M. Naccache, F. X. Blanc, A. Rabbat, D. Israel-Biet, D. Valeyre, C. Mayaud, and J. Cadranel.** 2004. Sarcoidosis in HIV-infected patients in the era of highly active antiretroviral therapy. *Clin. Infect. Dis.* **38:**418–425.
93. **Fox, P. A., S. E. Barton, N. Francis, M. Youle, D. C. Henderson, D. Pillay, M. A. Johnson, L. Fearfield, B. G. Gazzard, and C. B. Bunker.** 1999. Chronic erosive herpes simplex virus infection of the penis, a possible immune reconstitution disease. *HIV Med.* **1:**10–18.

94. **French, M. A.** 2006. The immunopathogenesis of mycobacterial immune restoration disease. *Lancet Infect. Dis.* **6:**461–462.
95. **French, M. A.** 2007. Disorders of immune reconstitution in patients with HIV infection responding to antiretroviral therapy. *Curr. HIV/AIDS Rep.* **4:**16–21.
96. **French, M. A., N. Lenzo, M. John, S. A. Mallal, E. J. McKinnon, I. R. James, P. Price, J. P. Flexman, and M. L. Tay-Kearney.** 2000. Immune restoration disease after the treatment of immunodeficient HIV-infected patients with highly active antiretroviral therapy. *HIV Med.* **1:**107–115.
97. **French, M. A., S. A. Mallal, and R. L. Dawkins.** 1992. Zidovudine-induced restoration of cell-mediated immunity to mycobacteria in immunodeficient HIV-infected patients. *AIDS* **6:**1293–1297.
98. **French, M. A., P. Price, and S. F. Stone.** 2004. Immune restoration disease after antiretroviral therapy. *AIDS* **18:**1615–1627.
99. **Gajdatsy, A. D., and M. L. Tay-Kearney.** 2001. Microsporidial keratoconjunctivitis after HAART. *Clin. Exp. Ophthalmol.* **29:**327–329.
100. **Gilad, J., A. Borer, D. Hallel-Halevy, K. Riesenberg, M. Alkan, and F. Schlaeffer.** 2001. Post-kala-azar dermal leishmaniasis manifesting after initiation of highly active anti-retroviral therapy in a patient with human immunodeficiency virus infection. *Isr. Med. Assoc. J.* **3:**451–452.
101. **Gilquin, J., C. Piketty, V. Thomas, G. Gonzales-Canali, L. Belec, and M. D. Kazatchkine.** 1997. Acute cytomegalovirus infection in AIDS patients with CD4 counts above 100×10^6 cells/l following combination antiretroviral therapy including protease inhibitors. *AIDS* **11:**1659–1660.
102. **Gilquin, J., J. P. Viard, V. Jubault, C. Sert, and M. D. Kazatchkine.** 1998. Delayed occurrence of Graves' disease after immune restoration with HAART. *Lancet* **352:**1907–1908.
103. **Goldsack, N. R., S. Allen, and M. C. Lipman.** 2003. Adult respiratory distress syndrome as a severe immune reconstitution disease following the commencement of highly active antiretroviral therapy. *Sex. Transm. Infect.* **79:**337–338.
104. **Gomez, V., P. R. Smith, J. Burack, R. Daley, and U. Rosa.** 2000. Sarcoidosis after antiretroviral therapy in a patient with acquired immunodeficiency syndrome. *Clin. Infect. Dis.* **31:**1278–1280.
105. **Gray, F., C. Bazille, H. Adle-Biassette, J. Mikol, A. Moulignier, and F. Scaravilli.** 2005. Central nervous system immune reconstitution disease in acquired immunodeficiency syndrome patients receiving highly active antiretroviral treatment. *J. Neurovirol.* **11**(Suppl. 3)**:**16–22.
106. **Greenspan, D., A. J. Canchola, L. A. MacPhail, B. Cheikh, and J. S. Greenspan.** 2001. Effect of highly active antiretroviral therapy on frequency of oral warts. *Lancet* **357:**1411–1412.
107. **Guex, A. C., H. C. Bucher, N. Demartines, U. Fluckiger, and M. Battegay.** 2002. Inflammatory bowel perforation during immune restoration after one year of antiretroviral and antituberculous therapy in an HIV-1-infected patient: report of a case. *Dis. Colon Rectum* **45:**977–978.
108. **Gupta, S., P. Mathur, D. Maskey, N. Wig, and S. Singh.** 2007. Immune restoration syndrome with disseminated Penicillium marneffei and cytomegalovirus co-infections in an AIDS patient. *AIDS Res. Ther.* **4:**21.
109. **Hammer, S. M., K. E. Squires, M. D. Hughes, J. M. Grimes, L. M. Demeter, J. S. Currier, J. J. Eron, Jr., J. E. Feinberg, H. H. Balfour, Jr., L. R. Deyton, J. A. Chodakewitz, M. A. Fischl, et al.** 1997. A controlled trial of two nucleoside analogues plus indinavir in persons with human immunodeficiency virus infection and CD4 cell counts of 200 per cubic millimeter or less. *N. Engl. J. Med.* **337:**725–733.
110. **Haramati, L. B., G. Lee, A. Singh, P. L. Molina, and C. S. White.** 2001. Newly diagnosed pulmonary sarcoidosis in HIV-infected patients. *Radiology* **218:**242–246.
111. **Hawkey, C. R., T. Yap, J. Pereira, D. A. Moore, R. N. Davidson, G. Pasvol, O. M. Kon, R. A. Wall, and R. J. Wilkinson.** 2005. Characterization and management of paradoxical upgrading reactions in HIV-uninfected patients with lymph node tuberculosis. *Clin. Infect. Dis.* **40:**1368–1371.
112. **Hirsch, H. H., G. Kaufmann, P. Sendi, and M. Battegay.** 2004. Immune reconstitution in HIV-infected patients. *Clin. Infect. Dis.* **38:**1159–1166.
113. **Holkova, B., K. Takeshita, D. M. Cheng, M. Volm, C. Wasserheit, R. Demopoulos, and A. Chanan-Khan.** 2001. Effect of highly active antiretroviral therapy on survival in patients with AIDS-associated pulmonary Kaposi's sarcoma treated with chemotherapy. *J. Clin. Oncol.* **19:**3848–3851.

114. **Holmes, C. B., R. Wood, M. Badri, S. Zilber, B. Wang, G. Maartens, H. Zheng, Z. Lu, K. A. Freedberg, and E. Losina.** 2006. CD4 decline and incidence of opportunistic infections in Cape Town, South Africa: implications for prophylaxis and treatment. *J. Acquir. Immune Defic. Syndr.* **42:**464–469.
115. **Huang, D. B., J. J. Wu, and R. J. Hamill.** 2004. Reactive hemophagocytosis associated with the initiation of highly active antiretroviral therapy (HAART) in a patient with AIDS. *Scand. J. Infect. Dis.* **36:**516–519.
116. **Huttner, H. B., R. Kollmar, A. Hug, F. Meisel, B. Kress, and S. Schwab.** 2004. Fatal tuberculous meningitis caused by immune restoration disease. *J. Neurol.* **251:**1522–1523.
117. **Huyst, V., L. Lynen, E. Bottieau, M. Zolfo, L. Kestens, and R. Colebunders.** 2007. Immune reconstitution inflammatory syndrome in an HIV/TB co-infected patient four years after starting antiretroviral therapy. *Acta Clin. Belg.* **62:**126–129.
118. **Ingiliz, P., B. Appenrodt, F. Gruenhage, M. Vogel, H. Tschampa, S. Tasci, and J. K. Rockstroh.** 2006. Lymphoid pneumonitis as an immune reconstitution inflammatory syndrome in a patient with CD4 cell recovery after HAART initiation. *HIV Med.* **7:**411–414.
119. **Intalapaporn, P., Y. Poovorawan, and C. Suankratay.** 2006. Immune reconstitution syndrome associated with parvovirus B19-induced pure red cell aplasia during highly active antiretroviral therapy. *J. Infect.* **53:**e79–e82.
120. **Jacobson, M. A.** 1997. Author's reply on comment on cytomegalovirus retinitis after initiation of highly active antiretroviral therapy. *Lancet* **350:**590.
121. **Jacobson, M. A.** 2006. Editorial comment: immune reconstitution inflammatory syndrome: not missing the forest for the trees. *AIDS Read.* **16:**214–215.
122. **Jacobson, M. A., M. Zegans, P. R. Pavan, J. J. O'Donnell, F. Sattler, N. Rao, S. Owens, and R. Pollard.** 1997. Cytomegalovirus retinitis after initiation of highly active antiretroviral therapy. *Lancet* **349:**1443–1445.
123. **Janowicz, D. M., R. M. Johnson, and S. K. Gupta.** 2005. Successful treatment of CMV ventriculitis immune reconstitution syndrome. *J. Neurol. Neurosurg. Psychiatry* **76:**891–892.
124. **Javid, B., S. H. Aliyu, V. E. Save, A. J. Carmichael, and A. M. Lever.** 2007. Schistosomal colonic polyposis in an HIV-positive man. *AIDS* **21:**386–388.
125. **Jehle, A. W., N. Khanna, J. P. Sigle, K. Glatz-Krieger, M. Battegay, J. Steiger, M. Dickenmann, and H. H. Hirsch.** 2004. Acute renal failure on immune reconstitution in an HIV-positive patient with miliary tuberculosis. *Clin. Infect. Dis.* **38:**e32–e35.
126. **Jenny-Avital, E. R., and M. Abadi.** 2002. Immune reconstitution cryptococcosis after initiation of successful highly active antiretroviral therapy. *Clin. Infect. Dis.* **35:**e128–e133.
127. **Jevtovic, D. J., D. Salemovic, J. Ranin, I. Pesic, S. Zerjav, and O. Djurkovic-Djakovic.** 2005. The prevalence and risk of immune restoration disease in HIV-infected patients treated with highly active antiretroviral therapy. *HIV Med.* **6:**140–143.
128. **Jimenez-Exposito, M. J., C. Alonso-Villaverde, P. Sarda, and L. Masana.** 1999. Visceral leishmaniasis in HIV-infected patients with non-detectable HIV-1 viral load after highly active antiretroviral therapy. *AIDS* **13:**152–153.
129. **John, L., J. Baalwa, P. Kalimugogo, E. Nabankema, B. Castelnuovo, G. Muhindo, R. Colebunders, and A. Kambugu.** 2005. Response to "Does immune reconstitution promote active tuberculosis in patients receiving highly active antiretroviral therapy?" *AIDS* **19:**2049–2050.
130. **John, M., J. Flexman, and M. A. French.** 1998. Hepatitis C virus-associated hepatitis following treatment of HIV-infected patients with HIV protease inhibitors: an immune restoration disease? *AIDS* **12:**2289–2293.
131. **John, M., and M. A. French.** 1998. Exacerbation of the inflammatory response to Mycobacterium tuberculosis after antiretroviral therapy. *Med. J. Aust.* **169:**473–474.
132. **Jubault, V., A. Penfornis, F. Schillo, B. Hoen, M. Izembart, J. Timsit, M. D. Kazatchkine, J. Gilquin, and J. P. Viard.** 2000. Sequential occurrence of thyroid autoantibodies and Graves' disease after immune restoration in severely immunocompromised human immunodeficiency virus-1-infected patients. *J. Clin. Endocrinol. Metab.* **85:**4254–4257.
133. **Kaplan, J. E., D. Hanson, M. S. Dworkin, T. Frederick, J. Bertolli, M. L. Lindegren, S. Holmberg, and J. L. Jones.** 2000. Epidemiology of human immunodeficiency virus-associated

opportunistic infections in the United States in the era of highly active antiretroviral therapy. *Clin. Infect. Dis.* **30**(Suppl. 1):S5–S14.

134. **Karavellas, M. P., S. P. Azen, J. C. Macdonald, C. L. Shufelt, C. Y. Lowder, D. J. Plummer, B. Glasgow, F. J. Torriani, and W. R. Freeman.** 2001. Immune recovery vitritis and uveitis in AIDS: clinical predictors, sequelae, and treatment outcomes. *Retina* **21**:1–9.
135. **Karavellas, M. P., D. J. Plummer, J. C. Macdonald, F. J. Torriani, C. L. Shufelt, S. P. Azen, and W. R. Freeman.** 1999. Incidence of immune recovery vitritis in cytomegalovirus retinitis patients following institution of successful highly active antiretroviral therapy. *J. Infect. Dis.* **179:** 697–700.
136. **Karavellas, M. P., M. Song, J. C. Macdonald, and W. R. Freeman.** 2000. Long-term posterior and anterior segment complications of immune recovery uveitis associated with cytomegalovirus retinitis. *Am. J. Ophthalmol.* **130:**57–64.
137. **Karras, A., C. Rabian, H. Zylberberg, O. Hermine, V. Duchatelle, F. Durand, D. Valla, and J. P. Viard.** 1998. Severe anoxic hepatic necrosis in an HIV-1-hepatitis C virus-co-infected patient starting antiretroviral triple combination therapy. *AIDS* **12:**827–829.
138. **Kastrup, O., I. Wanke, S. Esser, and M. Maschke.** 2005. Evolution of purely infratentorial PML under HAART-negative outcome under rapid immune reconstitution. *Clin. Neurol. Neurosurg.* **107:** 509–513.
139. **Kerob, D., J. D. Bouaziz, C. Sarfati, J. Pavie, M. D. Vignon-Pennamen, J. Menotti, S. Hamane, F. Pralong, P. Buffet, P. Morel, and C. Lebbe.** 2006. First case of cutaneous reconstitution inflammatory syndrome associated with HIV infection and leishmaniasis. *Clin. Infect. Dis.* **43:**664–666.
140. **Kerob, D., A. Dupuy, M. D. Vignon-Pennamen, I. Bournerias, E. Dohin, and C. Lebbe.** 2007. A case of efflorescence of cutaneous warts as a manifestation of immune reconstitution inflammatory syndrome in an HIV-infected patient. *Clin. Infect. Dis.* **45:**405–406.
141. **Kim, A. C., and H. C. Lupatkin.** 2004. Strongyloides stercoralis infection as a manifestation of immune restoration syndrome. *Clin. Infect. Dis.* **39:**439–440.
142. **King, M. D., C. A. Perlino, J. Cinnamon, and J. A. Jernigan.** 2002. Paradoxical recurrent meningitis following therapy of cryptococcal meningitis: an immune reconstitution syndrome after initiation of highly active antiretroviral therapy. *Int. J. STD AIDS* **13:**724–726.
143. **King, M. D., D. A. Reznik, C. M. O'Daniels, N. M. Larsen, D. Osterholt, and H. M. Blumberg.** 2002. Human papillomavirus-associated oral warts among human immunodeficiency virus-seropositive patients in the era of highly active antiretroviral therapy: an emerging infection. *Clin. Infect. Dis.* **34:**641–648.
144. **Knysz, B., M. Bolanowski, M. Klimczak, A. Gladysz, and K. Zwolinska.** 2006. Graves' disease as an immune reconstitution syndrome in an HIV-1-positive patient commencing effective antiretroviral therapy: case report and literature review. *Viral Immunol.* **19:**102–107.
145. **Knysz, B., M. Kuliszkiewicz-Janus, M. Jelen, R. Podlasin, and A. Gladysz.** 2006. Non-Hodgkin's lymphoma as a rare manifestation of immune reconstitution disease in HIV-1 positive patients. *Postepy Hig. Med. Dosw.* **60:**547–551.
146. **Knysz, B., M. Zalewska, M. Rzeszutko, and A. Gladysz.** 2006. Lung cancer as an immune reconstitution disease in an HIV-1 positive man receiving HAART. *Postepy Hig. Med. Dosw.* **60:** 181–183.
147. **Kosobucki, B. R., D. E. Goldberg, K. Bessho, H. J. Koh, N. Rodanant, L. Labree, L. Cheng, R. D. Schrier, S. P. Azen, and W. R. Freeman.** 2004. Valganciclovir therapy for immune recovery uveitis complicated by macular edema. *Am. J. Ophthalmol.* **137:**636–638.
148. **Koval, C. E., F. Gigliotti, D. Nevins, and L. M. Demeter.** 2002. Immune reconstitution syndrome after successful treatment of Pneumocystis carinii pneumonia in a man with human immunodeficiency virus type 1 infection. *Clin. Infect. Dis.* **35:**491–493.
149. **Kumarasamy, N., S. Chaguturu, K. H. Mayer, S. Solomon, H. T. Yepthomi, P. Balakrishnan, and T. P. Flanigan.** 2004. Incidence of immune reconstitution syndrome in HIV/tuberculosis-coinfected patients after initiation of generic antiretroviral therapy in India. *J. Acquir. Immune Defic. Syndr.* **37:**1574–1576.
150. **Kunimoto, D. Y., L. Chui, E. Nobert, and S. Houston.** 1999. Immune mediated "HAART" attack during treatment for tuberculosis. *Int. J. Tuberc. Lung Dis.* **3:**944–947.

151. **Langford, T. D., S. L. Letendre, T. D. Marcotte, R. J. Ellis, J. A. McCutchan, I. Grant, M. E. Mallory, L. A. Hansen, S. Archibald, T. Jernigan, and E. Masliah.** 2002. Severe, demyelinating leukoencephalopathy in AIDS patients on antiretroviral therapy. *AIDS* **16:**1019–1029.
152. **Lanzafame, M., F. Faggian, E. Lattuada, D. Antolini, and S. Vento.** 2005. Strongyloidiasis in an HIV-1-infected patient after highly active antiretroviral therapy-induced immune restoration. *J. Infect. Dis.* **191:**1027.
153. **Lawn, S. D.** 2005. Acute respiratory failure due to Mycobacterium kansasii infection: immune reconstitution disease in a patient with AIDS. *J. Infect.* **51:**339–340.
154. **Lawn, S. D., M. Badri, and R. Wood.** 2005. Tuberculosis among HIV-infected patients receiving HAART: long term incidence and risk factors in a South African cohort. *AIDS* **19:**2109–2116.
155. **Lawn, S. D., L. G. Bekker, and R. F. Miller.** 2005. Immune reconstitution disease associated with mycobacterial infections in HIV-infected individuals receiving antiretrovirals. *Lancet Infect. Dis.* **5:**361–373.
156. **Lawn, S. D., L. G. Bekker, L. Myer, C. Orrell, and R. Wood.** 2005. Cryptococcocal immune reconstitution disease: a major cause of early mortality in a South African antiretroviral programme. *AIDS* **19:**2050–2052.
157. **Lawn, S. D., T. A. Bicanic, and D. C. Macallan.** 2004. Pyomyositis and cutaneous abscesses due to Mycobacterium avium: an immune reconstitution manifestation in a patient with AIDS. *Clin. Infect. Dis.* **38:**461–463.
158. **Lawn, S. D., A. Checkley, and M. H. Wansbrough-Jones.** 2005. Acute bilateral parotitis caused by Mycobacterium scrofulaceum: immune reconstitution disease in a patient with AIDS. *Sex. Transm. Infect.* **81:**517–518.
159. **Lawn, S. D., and M. French.** 2007. Immune reconstitution disease: recent developments and implications for antiretroviral treatment in resource-limited settings. *Curr. Opin. HIV AIDS* **2:**339–345.
160. **Lawn, S. D., and D. N. Lockwood.** 2007. Leprosy after starting antiretroviral treatment. *BMJ* **334:** 217–218.
161. **Lawn, S. D., and D. C. Macallan.** 2004. Hypercalcemia: a manifestation of immune reconstitution complicating tuberculosis in an HIV-infected person. *Clin. Infect. Dis.* **38:**154–155.
162. **Lawn, S. D., L. Myer, L. G. Bekker, and R. Wood.** 2006. Burden of tuberculosis in an antiretroviral treatment programme in sub-Saharan Africa: impact on treatment outcomes and implications for tuberculosis control. *AIDS* **20:**1605–1612.
163. **Lawn, S. D., L. Myer, L. G. Bekker, and R. Wood.** 2007. Tuberculosis-associated immune reconstitution disease: incidence, risk factors and impact in an antiretroviral treatment service in South Africa. *AIDS* **21:**335–341.
164. **Lawn, S. D., and R. J. Wilkinson.** 2006. Immune reconstitution disease associated with parasitic infections following antiretroviral treatment. *Parasite Immunol.* **28:**625–633.
165. **Lawn, S. D., C. Wood, and D. N. Lockwood.** 2003. Borderline tuberculoid leprosy: an immune reconstitution phenomenon in a human immunodeficiency virus-infected person. *Clin. Infect. Dis.* **36:**e5–e6.
166. **Lawn, S. D., and R. Wood.** 2007. When should antiretroviral treatment be started in patients with HIV-associated tuberculosis in South Africa? *S. Afr. Med. J.* **97:**412–415.
167. **Legendre, U., M. Battegay, I. Nuttli, P. Dalquen, and R. Nuesch.** 2001. Simultaneous occurrence of 2 HIV-related immunereconstitution diseases after initiation of highly active antiretroviral therapy. *Scand. J. Infect. Dis.* **33:**388–389.
168. **Lehloenya, R., and G. Meintjes.** 2006. Dermatologic manifestations of the immune reconstitution inflammatory syndrome. *Dermatol. Clin.* **24:**549–570.
169. **Leidner, R. S., and D. M. Aboulafia.** 2005. Recrudescent Kaposi's sarcoma after initiation of HAART: a manifestation of immune reconstitution syndrome. *AIDS Patient Care STDS* **19:**635–644.
170. **Lenner, R., Z. Bregman, A. S. Teirstein, and L. DePalo.** 2001. Recurrent pulmonary sarcoidosis in HIV-infected patients receiving highly active antiretroviral therapy. *Chest* **119:**978–981.
171. **Lipman, M., and R. Breen.** 2006. Immune reconstitution inflammatory syndrome in HIV. *Curr. Opin. Infect. Dis.* **19:**20–25.

172. **Lipman, M. C., and S. K. Carding.** 2007. Successful drug treatment of immune reconstitution disease with the leukotriene receptor antagonist, montelukast: a clue to pathogenesis? *AIDS* **21:** 383–384.
173. **Lortholary, O.** 2007. Management of cryptococcal meningitis in AIDS: the need for specific studies in developing countries. *Clin. Infect. Dis.* **45:**81–83.
174. **Lortholary, O., A. Fontanet, N. Memain, A. Martin, K. Sitbon, and F. Dromer.** 2005. Incidence and risk factors of immune reconstitution inflammatory syndrome complicating HIV-associated cryptococcosis in France. *AIDS* **19:**1043–1049.
175. **Lowery, W. S., W. L. Whitlock, R. A. Dietrich, and J. M. Fine.** 1990. Sarcoidosis complicated by HIV infection: three case reports and a review of the literature. *Am. Rev. Respir. Dis.* **142:**887–889.
176. **Lucas, S. B., A. Hounnou, C. Peacock, A. Beaumel, G. Djomand, J. M. N'Gbichi, K. Yeboue, M. Honde, M. Diomande, C. Giordano, et al.** 1993. The mortality and pathology of HIV infection in a west African city. *AIDS* **7:**1569–1579.
177. **Makela, P., L. Howe, S. Glover, I. Ferguson, A. Pinto, and M. Gompels.** 2002. Recurrent Guillain-Barre syndrome as a complication of immune reconstitution in HIV. *J. Infect.* **44:**47–49.
178. **Manabe, Y. C., J. D. Campbell, E. Sydnor, and R. D. Moore.** 2007. Immune reconstitution inflammatory syndrome: risk factor and treatment implications. *J. Acquir. Immune Defic. Syndr.* **46:** 456–462.
179. **Manfredi, R., L. Calza, and F. Chiodo.** 2003. AIDS-associated Cryptococcus infection before and after the highly active antiretroviral therapy era: emerging management problems. *Int. J. Antimicrob. Agents* **22:**449–452.
180. **Manfredi, R., F. Pieri, S. A. Pileri, and F. Chiodo.** 1999. The changing face of AIDS-related opportunism: cryptococcosis in the highly active antiretroviral therapy (HAART) era. Case reports and literature review. *Mycopathologia* **148:**73–78.
181. **Manosuthi, W., S. Kiertiburanakul, T. Phoorisri, and S. Sungkanuparph.** 2006. Immune reconstitution inflammatory syndrome of tuberculosis among HIV-infected patients receiving antituberculous and antiretroviral therapy. *J. Infect.* **53:**357–363.
182. **Martinez, E., J. Gatell, Y. Moran, E. Aznar, E. Buira, A. Guelar, J. Mallolas, and E. Soriano.** 1998. High incidence of herpes zoster in patients with AIDS soon after therapy with protease inhibitors. *Clin. Infect. Dis.* **27:**1510–1513.
183. **Martiniuk, F., S. D. Rao, T. H. Rea, M. S. Glickman, J. Giovinazzo, W. N. Rom, A. Cabrera, and W. R. Levis.** 2007. Leprosy as immune reconstitution inflammatory syndrome in HIV-positive persons. *Emerg. Infect. Dis.* **13:**1438–1440.
184. **May, M., J. A. Sterne, C. Sabin, D. Costagliola, A. C. Justice, R. Thiebaut, J. Gill, A. Phillips, P. Reiss, R. Hogg, B. Ledergerber, M. A. D'Arminio, N. Schmeisser, S. Staszewski, and M. Egger.** 2007. Prognosis of HIV-1-infected patients up to 5 years after initiation of HAART: collaborative analysis of prospective studies. *AIDS* **21:**1185–1197.
185. **Mayanja-Kizza, H., E. Jones-Lopez, A. Okwera, R. S. Wallis, J. J. Ellner, R. D. Mugerwa, and C. C. Whalen.** 2005. Immunoadjuvant prednisolone therapy for HIV-associated tuberculosis: a phase 2 clinical trial in Uganda. *J. Infect. Dis.* **191:**856–865.
186. **McGovern, B.** 2004. What drives hepatitis B virus-related hepatic flares? Virus, T cells—or a bit of both? *Clin. Infect. Dis.* **39:**133–135.
187. **Michailidis, C., A. L. Pozniak, S. Mandalia, S. Basnayake, M. R. Nelson, and B. G. Gazzard.** 2005. Clinical characteristics of IRIS syndrome in patients with HIV and tuberculosis. *Antivir. Ther.* **10:**417–422.
188. **Michelet, C., C. Arvieux, C. Francois, J. M. Besnier, J. P. Rogez, J. P. Breux, F. Souala, C. Allavena, F. Raffi, M. Garre, and F. Cartier.** 1998. Opportunistic infections occurring during highly active antiretroviral treatment. *AIDS* **12:**1815–1822.
189. **Miller, R. F., P. J. Shaw, and I. G. Williams.** 2000. Immune reconstitution CMV pneumonitis. *Sex. Transm. Infect.* **76:**60.
190. **Miralles, P., J. Berenguer, C. Lacruz, J. Cosin, J. C. Lopez, B. Padilla, L. Munoz, and D. Garcia-de-Viedma.** 2001. Inflammatory reactions in progressive multifocal leukoencephalopathy after highly active antiretroviral therapy. *AIDS* **15:**1900–1902.

191. **Mirmirani, P., T. A. Maurer, B. Herndier, M. McGrath, M. D. Weinstein, and T. G. Berger.** 1999. Sarcoidosis in a patient with AIDS: a manifestation of immune restoration syndrome. *J. Am. Acad. Dermatol.* **41:**285–286.
192. **Mody, G. M., F. A. Parke, and J. D. Reveille.** 2003. Articular manifestations of human immunodeficiency virus infection. *Best Pract. Res. Clin. Rheumatol.* **17:**265–287.
193. **Mohammed, A., R. Ehrlich, R. Wood, F. Cilliers, and G. Maartens.** 2004. Screening for tuberculosis in adults with advanced HIV infection prior to preventive therapy. *Int. J. Tuberc. Lung Dis.* **8:**792–795.
194. **Monsuez, J. J., D. Vittecoq, L. Musset, M. Alemanni, E. Dussaix, and B. Autran.** 1998. Arthralgias and cryoglobulinemia during protease inhibitor therapy in a patient infected with human immunodeficiency virus and hepatitis C virus. *Arthritis Rheum.* **41:**740–743.
195. **Moussa, R., I. Stephenson, P. Fisk, J. Dhar, K. G. Nicholson, and M. J. Wiselka.** 2004. Buschke-Loewenstein lesion: another possible manifestation of immune restoration inflammatory syndrome? *AIDS* **18:**1221–1223.
196. **Moyle, M., I. J. Woolley, I. Thevarajan, and T. M. Korman.** 2004. Eosinophilic folliculitis: an example of "immune reconstitution folliculitis"? *AIDS* **18:**2350–2352.
197. **Murcia, J. M., V. Boix, E. Merino, M. I. Manso, and J. Portilla.** 2002. Drug toxicity or syndrome of immune restoration causing fulminant cirrhosis after HAART-induced immune recovery. *Eur. J. Clin. Microbiol. Infect. Dis.* **21:**153–155.
198. **Murdoch, D. M., W. D. Venter, A. Van Rie, and C. Feldman.** 2007. Immune reconstitution inflammatory syndrome (IRIS): review of common infectious manifestations and treatment options. *AIDS Res. Ther.* **4:**9.
199. **Murray, C. A., J. DeKoven, and D. E. Spaner.** 2003. Foreign body granuloma: a new manifestation of immune restoration syndrome. *J. Cutan. Med. Surg.* **7:**38–42.
200. **Murray, R., S. Mallal, C. Heath, and M. French.** 2001. Cerebral mycobacterium avium infection in an HIV-infected patient following immune reconstitution and cessation of therapy for disseminated mycobacterium avium complex infection. *Eur. J. Clin. Microbiol. Infect. Dis.* **20:**199–201.
201. **Mutimer, H. P., Y. Akatsuka, T. Manley, E. L. Chuang, M. Boeckh, R. Harrington, T. Jones, and S. R. Riddell.** 2002. Association between immune recovery uveitis and a diverse intraocular cytomegalovirus-specific cytotoxic T cell response. *J. Infect. Dis.* **186:**701–705.
202. **Mwaungulu, F. B. D., S. Floyd, and A. C. Crampin.** 2004. Cotrimoxazole prophylaxis reduces mortality in human immunodeficiency virus-positive tuberculosis patients in Karonga District, Malawi. *Bull. W. H. O.* **82:**354–363.
203. **Naccache, J. M., M. Antoine, M. Wislez, J. Fleury-Feith, E. Oksenhendler, C. Mayaud, and J. Cadranel.** 1999. Sarcoid-like pulmonary disorder in human immunodeficiency virus-infected patients receiving antiretroviral therapy. *Am. J. Respir. Crit. Care Med.* **159:**2009–2013.
204. **Narita, M., D. Ashkin, E. S. Hollender, and A. E. Pitchenik.** 1998. Paradoxical worsening of tuberculosis following antiretroviral therapy in patients with AIDS. *Am. J. Respir. Crit. Care Med.* **158:**157–161.
205. **Navas, E., P. Martin-Davila, L. Moreno, V. Pintado, J. L. Casado, J. Fortun, M. J. Perez-Elias, E. Gomez-Mampaso, and S. Moreno.** 2002. Paradoxical reactions of tuberculosis in patients with the acquired immunodeficiency syndrome who are treated with highly active antiretroviral therapy. *Arch. Intern. Med.* **162:**97–99.
206. **Neumann, S., F. Kreth, S. Schubert, J. Mossner, and K. Caca.** 2003. Reiter's syndrome as a manifestation of an immune reconstitution syndrome in an HIV-infected patient: successful treatment with doxycycline. *Clin. Infect. Dis.* **36:**1628–1629.
207. **Nolan, R. C., G. Chidlow, and M. A. French.** 2003. Parvovirus B19 encephalitis presenting as immune restoration disease after highly active antiretroviral therapy for human immunodeficiency virus infection. *Clin. Infect. Dis.* **36:**1191–1194.
208. **Olalla, J., F. Pulido, R. Rubio, M. A. Costa, R. Monsalvo, E. Palenque, J. R. Costa, and P. A. Del.** 2002. Paradoxical responses in a cohort of HIV-1-infected patients with mycobacterial disease. *Int. J. Tuberc. Lung Dis.* **6:**71–75.
209. **Palella, F. J., Jr., K. M. Delaney, A. C. Moorman, M. O. Loveless, J. Fuhrer, G. A. Satten, D. J. Aschman, S. D. Holmberg, et al.** 1998. Declining morbidity and mortality among patients with advanced human immunodeficiency virus infection. *N. Engl. J. Med.* **338:**853–860.

210. **Patton, L. L., R. McKaig, R. Strauss, D. Rogers, and J. J. Eron, Jr.** 2000. Changing prevalence of oral manifestations of human immuno-deficiency virus in the era of protease inhibitor therapy. *Oral Surg. Oral Med. Oral Pathol. Oral Radiol. Endod.* **89:**299–304.
211. **Phillips, P., S. Bonner, N. Gataric, T. Bai, P. Wilcox, R. Hogg, M. O'Shaughnessy, and J. Montaner.** 2005. Nontuberculous mycobacterial immune reconstitution syndrome in HIV-infected patients: spectrum of disease and long-term follow-up. *Clin. Infect. Dis.* **41:**1483–1497.
212. **Pignataro, P., R. A. Da Silva, J. A. Nery, A. Miranda, A. M. Sales, H. Ferrreira, V. Valentim, and P. N. Suffys.** 2004. Leprosy and AIDS: two cases of increasing inflammatory reactions at the start of highly active antiretroviral therapy. *Eur. J. Clin. Microbiol. Infect. Dis.* **23:**408–411.
213. **Piliero, P. J., D. G. Fish, S. Preston, D. Cunningham, T. Kinchelow, M. Salgo, J. Qian, and G. L. Drusano.** 2003. Guillain-Barre syndrome associated with immune reconstitution. *Clin. Infect. Dis.* **36:**e111–e114.
214. **Plasencia, L. D., M. M. Socas, R. A. Valls, E. M. Fernandez, A. C. Higuera, and A. B. Gutierrez.** 2006. Terminal ileitis as a manifestation of immune reconstitution syndrome following HAART. *AIDS* **20:**1903–1905.
215. **Posada-Vergara, M. P., J. A. Lindoso, J. E. Tolezano, V. L. Pereira-Chioccola, M. V. Silva, and H. Goto.** 2005. Tegumentary leishmaniasis as a manifestation of immune reconstitution inflammatory syndrome in 2 patients with AIDS. *J. Infect. Dis.* **192:**1819–1822.
216. **Powles, T., C. Thirlwell, M. Nelson, and M. Bower.** 2003. Immune reconstitution inflammatory syndrome mimicking relapse of AIDS related lymphoma in patients with HIV 1 infection. *Leuk. Lymphoma* **44:**1417–1419.
217. **Price, P., G. Morahan, D. Huang, E. Stone, K. Y. Cheong, A. Castley, M. Rodgers, M. Q. McIntyre, L. J. Abraham, and M. A. French.** 2002. Polymorphisms in cytokine genes define subpopulations of HIV-1 patients who experienced immune restoration diseases. *AIDS* **16:**2043–2047.
218. **Price, P., C. Witt, D. de Santis, and M. A. French.** 2007. Killer immunoglobulin-like receptor genotype may distinguish immunodeficient HIV-infected patients resistant to immune restoration diseases associated with herpes virus infections. *J. Acquir. Immune Defic. Syndr.* **45:**359–361.
219. **Puthanakit, T., L. Aurpibul, P. Oberdorfer, N. Akarathum, S. Kanjananit, P. Wannarit, T. Sirisanthana, and V. Sirisanthana.** 2007. Hospitalization and mortality among HIV-infected children after receiving highly active antiretroviral therapy. *Clin. Infect. Dis.* **44:**599–604.
220. **Puthanakit, T., P. Oberdorfer, N. Akarathum, P. Wannarit, T. Sirisanthana, and V. Sirisanthana.** 2006. Immune reconstitution syndrome after highly active antiretroviral therapy in human immunodeficiency virus-infected Thai children. *Pediatr. Infect. Dis. J.* **25:**53–58.
221. **Puthanakit, T., P. Oberdorfer, S. Punjaisee, P. Wannarit, T. Sirisanthana, and V. Sirisanthana.** 2005. Immune reconstitution syndrome due to bacillus Calmette-Guerin after initiation of antiretroviral therapy in children with HIV infection. *Clin. Infect. Dis.* **41:**1049–1052.
222. **Qazi, N. A., J. F. Morlese, J. C. Walsh, C. B. Bunker, N. Francis, and M. R. Nelson.** 2002. Case report. Severe cutaneous ulceration secondary to cytomegalovirus inclusion disease during successful immune reconstitution with HAART. *AIDS Read.* **12:**452–457.
223. **Race, E. M., J. Adelson-Mitty, G. R. Kriegel, T. F. Barlam, K. A. Reimann, N. L. Letvin, and A. J. Japour.** 1998. Focal mycobacterial lymphadenitis following initiation of protease-inhibitor therapy in patients with advanced HIV-1 disease. *Lancet* **351:**252–255.
224. **Rajendran, P. M., J. C. Dolev, M. R. Heaphy, Jr., and T. Maurer.** 2005. Eosinophilic folliculitis: before and after the introduction of antiretroviral therapy. *Arch. Dermatol.* **141:**1227–1231.
225. **Rajeswaran, G., J. L. Becker, C. Michailidis, A. L. Pozniak, and S. P. Padley.** 2006. The radiology of IRIS (immune reconstitution inflammatory syndrome) in patients with mycobacterial tuberculosis and HIV co-infection: appearances in 11 patients. *Clin. Radiol.* **61:**833–843.
226. **Rambeloarisoa, J., D. Batisse, J. B. Thiebaut, J. Mikol, S. Mrejen, M. Karmochkine, M. D. Kazatchkine, L. Weiss, and C. Piketty.** 2002. Intramedullary abscess resulting from disseminated cryptococcosis despite immune restoration in a patient with AIDS. *J. Infect.* **44:**185–188.
227. **Rana, F. S., M. P. Hawken, C. Mwachari, S. M. Bhatt, F. Abdullah, L. W. Ng'ang'a, C. Power, W. A. Githui, J. D. Porter, and S. B. Lucas.** 2000. Autopsy study of HIV-1-positive and HIV-1-negative adult medical patients in Nairobi, Kenya. *J. Acquir. Immune Defic. Syndr.* **24:**23–29.

228. **Ratnam, I., C. Chiu, N. B. Kandala, and P. J. Easterbrook.** 2006. Incidence and risk factors for immune reconstitution inflammatory syndrome in an ethnically diverse HIV type 1-infected cohort. *Clin. Infect. Dis.* **42:**418–427.
229. **Reddy, V., and G. A. Luzzi.** 2005. Chronic vulval ulceration—another immune reconstitution inflammatory syndrome? *Int. J. STD AIDS* **16:**454–455.
230. **Ridolfo, A. L., C. Gervasoni, S. Antinori, M. Pizzuto, S. Santambrogio, D. Trabattoni, M. Clerici, and M. Galli.** 2000. Post-kala-azar dermal leishmaniasis during highly active antiretroviral therapy in an AIDS patient infected with Leishmania infantum. *J. Infect.* **40:**199–202.
231. **Robertson, J., M. Meier, J. Wall, J. Ying, and C. J. Fichtenbaum.** 2006. Immune reconstitution syndrome in HIV: validating a case definition and identifying clinical predictors in persons initiating antiretroviral therapy. *Clin. Infect. Dis.* **42:**1639–1646.
232. **Rogers, G. D., and M. A. French.** 2004. Peyronie's disease in men with HIV responding to highly active antiretroviral therapy. *HIV Med.* **5:**185–186.
233. **Rosenfeld, C. R., and L. H. Calabrese.** 1999. Progression of autoimmune thyroiditis in an HIV-infected woman on HAART. *AIDS Read.* **9:**393–394, 397.
234. **Rutschmann, O. T., F. Negro, B. Hirschel, A. Hadengue, D. Anwar, and L. H. Perrin.** 1998. Impact of treatment with human immunodeficiency virus (HIV) protease inhibitors on hepatitis C viremia in patients coinfected with HIV. *J. Infect. Dis.* **177:**783–785.
235. **Safdar, A., R. J. Rubocki, J. A. Horvath, K. K. Narayan, and R. L. Waldron.** 2002. Fatal immune restoration disease in human immunodeficiency virus type 1-infected patients with progressive multifocal leukoencephalopathy: impact of antiretroviral therapy-associated immune reconstitution. *Clin. Infect. Dis.* **35:**1250–1257.
236. **Salama, C., M. Policar, and M. Venkataraman.** 2003. Isolated pulmonary Mycobacterium avium complex infection in patients with human immunodeficiency virus infection: case reports and literature review. *Clin. Infect. Dis.* **37:**e35–e40.
237. **Sambatakou, H., and D. W. Denning.** 2005. Invasive pulmonary aspergillosis transformed into fatal mucous impaction by immune reconstitution in an AIDS patient. *Eur. J. Clin. Microbiol. Infect. Dis.* **24:**628–633.
238. **Sansonetti, P., and P. H. Lagrange.** 1981. The immunology of leprosy: speculations on the leprosy spectrum. *Rev. Infect. Dis.* **3:**422–469.
239. **Schiffer, J. T., and T. R. Sterling.** 2007. Timing of antiretroviral therapy initiation in tuberculosis patients with AIDS: a decision analysis. *J. Acquir. Immune Defic. Syndr.* **44:**229–234.
240. **Schrier, R. D., M. K. Song, I. L. Smith, M. P. Karavellas, D. U. Bartsch, F. J. Torriani, C. R. Garcia, and W. R. Freeman.** 2006. Intraocular viral and immune pathogenesis of immune recovery uveitis in patients with healed cytomegalovirus retinitis. *Retina* **26:**165–169.
241. **Sellier, P., J. J. Monsuez, J. Evans, C. Minozzi, J. Passeron, D. Vittecoq, E. Dussaix, G. Carcelain, and C. Lacroix-Jousselin.** 2000. Human immunodeficiency virus-associated polymyositis during immune restoration with combination antiretroviral therapy. *Am. J. Med.* **109:**510–512.
242. **Sereti, I., N. J. Sarlis, E. Arioglu, M. L. Turner, and J. M. Mican.** 2001. Alopecia universalis and Graves' disease in the setting of immune restoration after highly active antiretroviral therapy. *AIDS* **15:**138–140.
243. **Sexton, D., and B. Pien.** 2007. Immune reconstitution inflammatory syndrome. *UpToDate.* http://www.uptodate.com/patients/content/topic.do?topicKey=hiv_infe/22741.
244. **Seyler, C., S. Toure, E. Messou, D. Bonard, D. Gabillard, and X. Anglaret.** 2005. Risk factors for active tuberculosis after antiretroviral treatment initiation in Abidjan. *Am. J. Respir. Crit. Care Med.* **172:**123–127.
245. **Shelburne, S. A., III, J. Darcourt, A. C. White, Jr., S. B. Greenberg, R. J. Hamill, R. L. Atmar, and F. Visnegarwala.** 2005. The role of immune reconstitution inflammatory syndrome in AIDS-related Cryptococcus neoformans disease in the era of highly active antiretroviral therapy. *Clin. Infect. Dis.* **40:**1049–1052.
246. **Shelburne, S. A., III, and R. J. Hamill.** 2003. The immune reconstitution inflammatory syndrome. *AIDS Rev.* **5:**67–79.
247. **Shelburne, S. A., III, R. J. Hamill, M. C. Rodriguez-Barradas, S. B. Greenberg, R. L. Atmar, D. W. Musher, J. C. Gathe, Jr., F. Visnegarwala, and B. W. Trautner.** 2002. Immune reconsti-

tution inflammatory syndrome: emergence of a unique syndrome during highly active antiretroviral therapy. *Medicine* (Baltimore) **81:**213–227.

248. **Shelburne, S. A., M. Montes, and R. J. Hamill.** 2006. Immune reconstitution inflammatory syndrome: more answers, more questions. *J. Antimicrob. Chemother.* **57:**167–170.
249. **Shelburne, S. A., III, F. Visnegarwala, C. Adams, K. L. Krause, R. J. Hamill, and A. C. White, Jr.** 2005. Unusual manifestations of disseminated Histoplasmosis in patients responding to antiretroviral therapy. *Am. J. Med.* **118:**1038–1041.
250. **Shelburne, S. A., F. Visnegarwala, J. Darcourt, E. A. Graviss, T. P. Giordano, A. C. White, Jr., and R. J. Hamill.** 2005. Incidence and risk factors for immune reconstitution inflammatory syndrome during highly active antiretroviral therapy. *AIDS* **19:**399–406.
251. **Siberry, G. K., and S. Tessema.** 2006. Immune reconstitution syndrome precipitated by bacille Calmette Guerin after initiation of antiretroviral therapy. *Pediatr. Infect. Dis. J.* **25:**648–649.
252. **Silva, M. T., M. C. Pacheco, Jr., and B. Vaz.** 2006. Inflammatory progressive multifocal leukoencephalopathy after antiretroviral treatment. *AIDS* **20:**469–471.
253. **Silvestre, J. F., M. P. Albares, R. Ramon, and R. Botella.** 2001. Cutaneous intolerance to tattoos in a patient with human immunodeficiency virus: a manifestation of the immune restoration syndrome. *Arch. Dermatol.* **137:**669–670.
254. **Singh, N., O. Lortholary, B. D. Alexander, K. L. Gupta, G. T. John, K. Pursell, P. Munoz, G. B. Klintmalm, V. Stosor, R. del Busto, A. P. Limaye, J. Somani, M. Lyon, S. Houston, A. A. House, T. L. Pruett, S. Orloff, A. Humar, L. Dowdy, J. Garcia-Diaz, A. C. Kalil, R. A. Fisher, and S. Husain.** 2005. An immune reconstitution syndrome-like illness associated with Cryptococcus neoformans infection in organ transplant recipients. *Clin. Infect. Dis.* **40:**1756–1761.
255. **Singh, N., and J. R. Perfect.** 2007. Immune reconstitution syndrome and exacerbation of infections after pregnancy. *Clin. Infect. Dis.* **45:**1192–1199.
256. **Singh, N., and J. R. Perfect.** 2007. Immune reconstitution syndrome associated with opportunistic mycoses. *Lancet Infect. Dis.* **7:**395–401.
257. **Skiest, D. J., L. J. Hester, and R. D. Hardy.** 2005. Cryptococcal immune reconstitution inflammatory syndrome: report of four cases in three patients and review of the literature. *J. Infect.* **51:** e289–e297.
258. **Smith, H.** 1987. Paradoxical responses during the chemotherapy of tuberculosis. *J. Infect.* **15:** 1–3.
259. **Song, M. K., S. P. Azen, A. Buley, F. Torriani, L. Cheng, S. Chaidhawangul, U. Ozerdem, B. Scholz, and W. R. Freeman.** 2003. Effect of anti-cytomegalovirus therapy on the incidence of immune recovery uveitis in AIDS patients with healed cytomegalovirus retinitis. *Am. J. Ophthalmol.* **136:**696–702.
260. **Stone, S. F., S. Lee, N. M. Keane, P. Price, and M. A. French.** 2002. Association of increased hepatitis C virus (HCV)-specific IgG and soluble CD26 dipeptidyl peptidase IV enzyme activity with hepatotoxicity after highly active antiretroviral therapy in human immunodeficiency virus-HCV-coinfected patients. *J. Infect. Dis.* **186:**1498–1502.
261. **Stone, S. F., P. Price, J. Brochier, and M. A. French.** 2001. Plasma bioavailable interleukin-6 is elevated in human immunodeficiency virus-infected patients who experience herpesvirus-associated immune restoration disease after start of highly active antiretroviral therapy. *J. Infect. Dis.* **184:** 1073–1077.
262. **Stone, S. F., P. Price, N. M. Keane, R. J. Murray, and M. A. French.** 2002. Levels of IL-6 and soluble IL-6 receptor are increased in HIV patients with a history of immune restoration disease after HAART. *HIV Med.* **3:**21–27.
263. **Stone, S. F., P. Price, M. L. Tay-Kearney, and M. A. French.** 2002. Cytomegalovirus (CMV) retinitis immune restoration disease occurs during highly active antiretroviral therapy-induced restoration of CMV-specific immune responses within a predominant Th2 cytokine environment. *J. Infect. Dis.* **185:**1813–1817.
264. **Subsai, K., S. Kanoksri, C. Siwaporn, L. Helen, O. Kanokporn, and P. Wantana.** 2006. Neurological complications in AIDS patients receiving HAART: a 2-year retrospective study. *Eur. J. Neurol.* **13:**233–239.
265. **Sungkanuparph, S., U. Jongwutiwes, and S. Kiertiburanakul.** 2007. Timing of cryptococcal immune reconstitution inflammatory syndrome after antiretroviral therapy in patients with AIDS and cryptococcal meningitis. *J. Acquir. Immune Defic. Syndr.* **45:**595–596.

266. **Tamburini, J., D. Grimaldi, J. D. Chiche, F. Bricaire, and P. Bossi.** 2007. Cytokine pattern in Kaposi's sarcoma associated with immune restoration disease in HIV and tuberculosis co-infected patients. *AIDS* **21:**1980–1983.
267. **Taylor, C. L., V. Subbarao, S. Gayed, and A. P. Ustianowski.** 2007. Immune reconstitution syndrome to Strongyloides stercoralis infection. *AIDS* **21:**649–650.
268. **Trevenzoli, M., A. M. Cattelan, F. Marino, U. Marchioro, and P. Cadrobbi.** 2003. Sarcoidosis and HIV infection: a case report and a review of the literature. *Postgrad. Med. J.* **79:**535–538.
269. **Trevenzoli, M., A. M. Cattelan, F. Rea, L. Sasset, M. Semisa, M. Lanzafame, F. Meneghetti, and P. Cadrobbi.** 2002. Mediastinitis due to cryptococcal infection: a new clinical entity in the HAART era. *J. Infect.* **45:**173–179.
270. **Tsambiras, P. E., J. A. Larkin, and S. H. Houston.** 2001. Case report. Toxoplasma encephalitis after initiation of HAART. *AIDS Read.* **11:**608–610.
271. **Ustianowski, A. P., S. D. Lawn, and D. N. Lockwood.** 2006. Interactions between HIV infection and leprosy: a paradox. *Lancet Infect. Dis.* **6:**350–360.
272. **van der Horst, C. M., M. S. Saag, G. A. Cloud, R. J. Hamill, J. R. Graybill, J. D. Sobel, P. C. Johnson, C. U. Tuazon, T. Kerkering, B. Moskovitz, W. G. Powderly, and W. E. Dismukes.** 1997. Treatment of cryptococcal meningitis in association with the acquired immunodeficiency syndrome. *N. Engl. J. Med.* **337:**15–21.
273. **van der Ven, A. J., R. J. van Oostenbrugge, B. Kubat, and J. W. Tervaert.** 2002. Cerebral vasculitis after initiation antiretroviral therapy. *AIDS* **16:**2362–2364.
274. **van Hal, S. J., and G. Kotsiou.** 2005. An HIV-positive man with generalized rash. *Clin. Infect. Dis.* **40:**113, 182–183.
275. **Velez, A. P., L. Menezes, and A. Crespo.** 2006. Kawasaki-like syndrome possibly associated with immune reconstitution inflammatory syndrome in an HIV-positive patient. *AIDS Read.* **16:**464–466.
276. **Vendrely, A., B. Bienvenu, J. Gasnault, J. B. Thiebault, D. Salmon, and F. Gray.** 2005. Fulminant inflammatory leukoencephalopathy associated with HAART-induced immune restoration in AIDS-related progressive multifocal leukoencephalopathy. *Acta Neuropathol.* **109:**449–455.
277. **Venkataramana, A., C. A. Pardo, J. C. McArthur, D. A. Kerr, D. N. Irani, J. W. Griffin, P. Burger, D. S. Reich, P. A. Calabresi, and A. Nath.** 2006. Immune reconstitution inflammatory syndrome in the CNS of HIV-infected patients. *Neurology* **67:**383–388.
278. **Verma, S., H. Bhakta, A. Nowain, S. Pais, G. Kanel, and K. Squires.** 2005. Severe cholestatic liver injury days after initiating antiretroviral therapy in a patient with AIDS: drug toxicity or immune reconstitution inflammatory syndrome? *Dig. Dis. Sci.* **50:**1813–1817.
279. **Vidal, J. E., M. C. Fink, F. Cedeno-Laurent, S. Delbue, P. Ferrante, R. F. Dauar, F. B. Filho, R. S. Nogueira, E. E. Calore, C. S. Pannuti, J. R. Trujillo, and A. C. de Oliveira.** 2007. BK virus associated meningoencephalitis in an AIDS patient treated with HAART. *AIDS Res. Ther.* **4:** 13.
280. **Vos, F., G. Pieters, M. Keuter, and A. van der Ven.** 2006. Graves' disease during immune reconstitution in HIV-infected patients treated with HAART. *Scand. J. Infect. Dis.* **38:**124–126.
281. **Wendel, K. A., K. S. Alwood, R. Gachuhi, R. E. Chaisson, W. R. Bishai, and T. R. Sterling.** 2001. Paradoxical worsening of tuberculosis in HIV-infected persons. *Chest* **120:**193–197.
282. **WHO.** 2006. Antiretroviral therapy for HIV infection in adults and adolescents in resource-limited settings: towards universal access. WHO, Geneva, Switzerland.
283. **Wislez, M., E. Bergot, M. Antoine, A. Parrot, M. F. Carette, C. Mayaud, and J. Cadranel.** 2001. Acute respiratory failure following HAART introduction in patients treated for Pneumocystis carinii pneumonia. *Am. J. Respir. Crit. Care Med.* **164:**847–851.
284. **Wood, R., G. Maartens, and C. J. Lombard.** 2000. Risk factors for developing tuberculosis in HIV-1-infected adults from communities with a low or very high incidence of tuberculosis. *J. Acquir. Immune Defic. Syndr.* **23:**75–80.
285. **Woods, M. L., R. MacGinley, D. P. Eisen, and A. M. Allworth.** 1998. HIV combination therapy: partial immune restitution unmasking latent cryptococcal infection. *AIDS* **12:**1491–1494.
286. **York, J., I. Bodi, I. Reeves, P. Riordan-Eva, and P. J. Easterbrook.** 2005. Raised intracranial pressure complicating cryptococcal meningitis: immune reconstitution inflammatory syndrome or recurrent cryptococcal disease? *J. Infect.* **51:**165–171.

287. **Zandman-Goddard, G., E. Peeva, and P. Barland.** 2002. Combined autoimmune disease in a patient with AIDS. *Clin. Rheumatol.* **21:**70–72.
288. **Zylberberg, H., G. Pialoux, F. Carnot, A. Landau, C. Brechot, and S. Pol.** 1998. Rapidly evolving hepatitis C virus-related cirrhosis in a human immunodeficiency virus-infected patient receiving triple antiretroviral therapy. *Clin. Infect. Dis.* **27:**1255–1258.