

CASE REPORT

DIAGNOSTIC DELAY IN A MULTI-ORGAN TUBERCULOSIS IMMUNOCOMPETENT PATIENT: A CASE REPORT

PV Kishore¹, Subish Palaian², Raju Paudel¹, Mukhyaprana Prabhu³ and Jef Van Den Ende⁴

¹Department of Medicine, ²Department of Hospital and Clinical Pharmacy, Manipal Teaching Hospital/Manipal College of Medical Sciences, Pokhara, Nepal; ³Department of Medicine, Kasturba Medical College, Manipal, Karnataka, India; ⁴Department of Clinical Sciences, Institute of Tropical Medicine, Antwerp, Belgium

Abstract. A 67-year-old immunocompetent male presented with intermittent fever for 3 months associated with urinary incontinence, altered bowel habits and history of loss of appetite and weight. He was treated as having enteric fever at various clinics in the city by different physicians. On evaluation the patient was found to have disseminated tuberculosis with involvement of the lungs, eyes, testes, brain, bone, kidneys, liver, spleen and possibly the gastrointestinal tract. This paper reports a case of disseminated tuberculosis to many organs with significant diagnostic delay more than twelve decades after the discovery of the tuberculosis bacillus by Robert Koch.

INTRODUCTION

Evidence of tuberculosis (TB) has been documented in the bones of prehistoric man from Germany from as early as 5000 B.C. On March 24, 1882, Robert Koch discovered *Tuberculosis bacillus* (TB) and announced his discovery at a clinical meeting in Berlin. In 1993, the World Health Organization (WHO) declared TB a global emergency and started directly observed treatment, short course (DOTS) programs in countries all over the world (Nehaul, 2003). In Nepal, TB is a well known disease with an estimated 6,000-8,000 deaths every year (National Tuberculosis Programme, 1995). In Nepal, following a joint government/WHO review of the Nepal National Tuberculosis Programme (NTP) in 1994, DOTS was adopted as national policy in 1995, with implementation starting in early 1996 (National

Correspondence: PV Kishore, Department of Medicine, Manipal Teaching Hospital/Manipal College of Medical Sciences, Pokhara, Nepal.
E-mail: pandu_vki@yahoo.com

Tuberculosis Programme, 1995). Disseminated TB can result from two distinct pathogenic sequences, occurring either as an early consequence of initial infection and bacillemia or as a result of endogenous reactivation and blood stream invasion (Hopewell and Bloom, 2000). When a TB lesion leaks into a blood vessel, massive dissemination of organisms may occur, causing millions of 1-3 mm metastatic lesions. Such spread is named as miliary because the lesions resemble millet seeds (Beers and Berkow, 1999). Classic miliary TB is defined as millet like (mean 2 mm, range 1-5 mm) seeding of the TB bacilli in the lung, as evidenced on chest radiograph. This pattern is seen in 1-3% of all TB cases (Beers and Berkow, 1999; Lessnau and de Luise, 2006). Some predisposing factors include cancer, transplantation, HIV infection, malnutrition, diabetes, silicosis, end-stage renal disease, major surgical procedures (Lessnau and de Luise, 2006) and old age (Hopewell and Bloom, 2000). Figures of the incidence of miliary TB in Nepal are lacking. We report here a

case of miliary TB in a 67-year-old male.

CASE REPORT

A 67-year-old, non-hypertensive, non-diabetic, non-smoking, social drinking patient was admitted to our hospital with complaint of intermittent fever for 3 months, incontinence of urine, diarrhea alternating with constipation, loss of weight and appetite. Prior to admission to our hospital the patient was treated as having enteric fever by private practitioners. Upon presentation, the patient was febrile, conscious, coherent and co-operative. There was no lymphadenopathy. The lungs were clear, cardiac auscultation was unremarkable. Abdominal examination revealed hepato-splenomegaly. The nervous system examination was normal. Fundoscopy revealed yellowish small lesions suggestive of choroid tubercles (Fig 1). Scrotal examination revealed a left sided 2/2 cm mass, hard in consistency, non-tender with loss of testicular sensation. High resolution ultrasound of the scrotum showed bilateral chronic epididymo-orchitis.

The investigations done were WBC $7,500/\text{mm}^3$, ESR 20 mm/1 hr, urine microscopy with plenty of WBCs, serum albumin 2.8 g/dl (3.2-5.5), SGOT 63 μl (5-40), SGPT 47 μl (5-40), ALP 566 U/l; sodium 121 mEq/dl and potassium 3.6 mEq/dl. Renal function was normal. The HIV spot test was non-reactive. Sputum did not reveal acid-fast bacilli in three early morning samples. Urine for culture revealed no growth in spite of plenty of white cells on microscopy (sterile pyuria). The specimen was not cultured for TB due to a lack of adequate laboratory facilities. The chest radiograph showed multiple small nodular shadows distributed bilaterally (Fig 2). Abdominal ultrasonography revealed hepato-splenomegaly and an enlarged prostate. Bladder, ureters and kidneys were reportedly normal.

On day 3, taking into account the chronic pyrexia and miliary pattern of the chest radio-

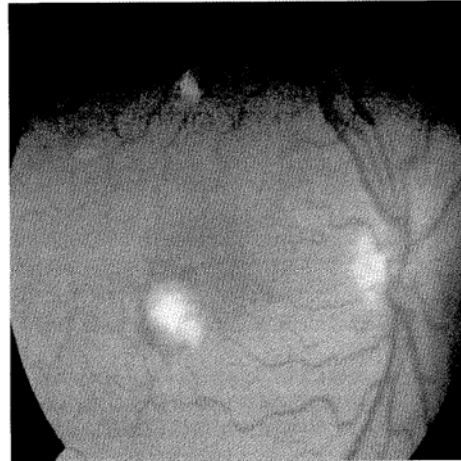


Fig 1-Fundus showing choroid tubercle.

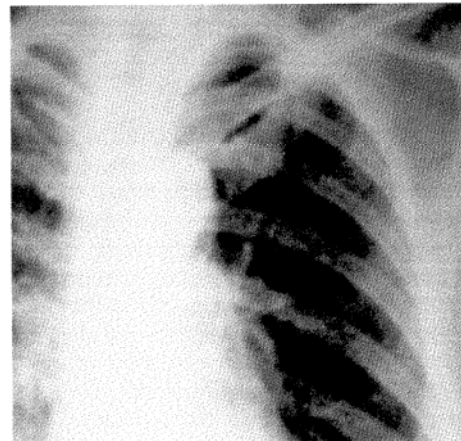


Fig 2-Chest radiograph at presentation with miliary mottling.

graph, the patient was started on a category 1 regimen of antituberculous therapy from the local DOTS center (MTH) and on oral prednisolone. On day 4 the patient became drowsy with neuropsychiatric symptoms, including disturbed sleep and irrelevant speech. Contrast enhanced CT brain showed multiple ring

enhancing supratentorial lesions in the right cerebral hemisphere with peri-focal edema suggestive of multiple tuberculomata (Fig 3).

On day 5, the prednisolone was stopped and the patient was started on injectable dexamethasone 4 mg 8 hourly, which was later changed to oral dexamethasone and tapered slowly over a month, the neuropsychiatric symptoms subsequently improved.

On day 9, the patient complained of left shoulder pain and an X-ray showed thinned out cortex and lytic lesions in the acromian process, the glenoid cavity and the area around the head of the humerus with mid shaft periosteal reaction and calcification (Fig 4).

On day 11, the patient was clinically improving, but he developed an urticarial rash with itching all over the body. A dermatologist suggested drug induced rash, most probably either due to isoniazid or rifampicin. Both drugs were withdrawn and replaced with injectable amikacin 750 mg once daily and ofloxacin 400 mg twice daily.

On day 16, the patient had increased swelling and pain of the scrotum. A biopsy was sent for histopathology and pus was drained for various stainings. The pathologist reported granulomatous epididymitis. The pus showed acid-fast bacilli on Ziehl-Nielsen staining and few *Staphylococcus aureus* on Gram's stain.

On day 19, the skin rash subsided, and isoniazid and rifampicin were restarted sequentially with challenging doses (WHO guidelines) with no recurrence of rash. The patient was discharged on day 30. He was on regular follow-up with no new complaints with clinical, biochemical and radiological improvement of all the systems involved.

DISCUSSION

The clinical manifestations of miliary TB are non-specific and protean and depend on

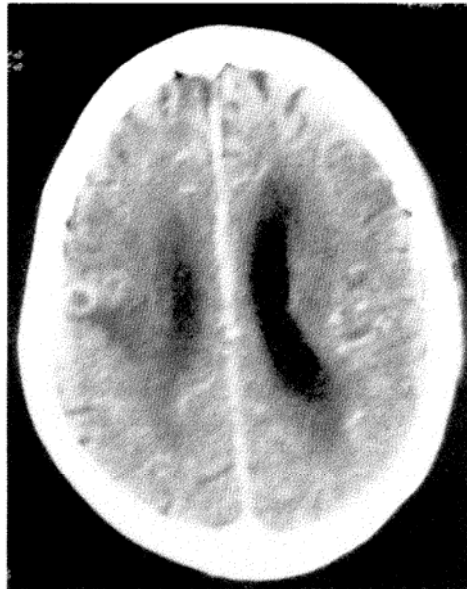

Fig 3—Ring enhancing lesion in CT brain.

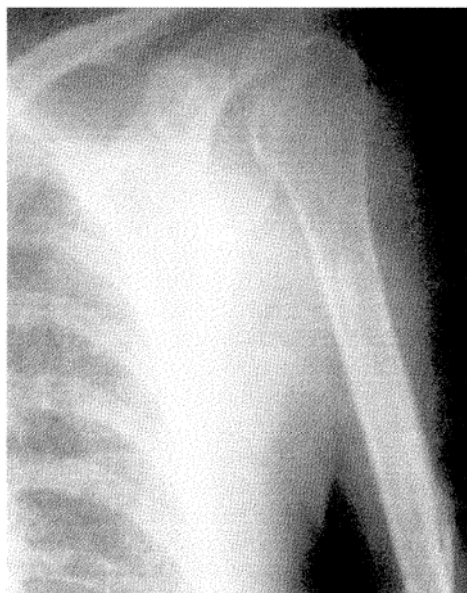

Fig 4—Radiograph of shoulder with lytic lesions.

the site involved. Fever, night sweats, anorexia, weakness, and weight loss are presenting symptoms in many cases. Hepatomegaly, splenomegaly and lymphadenopathy may also be present (Raviglione and O'Brien, 2001). Our patient had complaints of fever for nearly 3 months, incontinence of urine and diarrhea followed by constipation with a loss of weight and appetite. Lymphadenopathy was not evident in our patient. However, hepato-splenomegaly was present. Apart from weight loss, the most frequent metabolic effect is hyponatremia and the most frequent abnormality of liver function is an increase alkaline phosphatase concentration (Chung and Hubbard, 1969). A similar finding was observed in our patient as well.

Multiorgan involvement is probably a more common occurrence than is recognized, because once *M. tuberculosis* is identified on any specimen, other sites are not evaluated (Hopewell and Bloom, 2000). The only physical finding that was specific for disseminated TB was the choroid tubercle, a granuloma located in the choroid of the retina (Hopewell and Bloom, 2000). Autopsy series have shown the liver, lungs, bone marrow, kidneys, adrenal glands and spleen to be the organs most frequently involved in miliary TB, but any organ can be the site of disease (Slavin *et al*, 1980). In our case the systems involved were respiratory (miliary), scrotum (epididymitis), renal (sterile pyuria), eyes (choroid tubercles), central nervous system (multiple tuberculomata), bone (humerus), liver, spleen and probably gastrointestinal system, as the patient had symptoms of alternating diarrhea and constipation.

Disseminated TB must be treated promptly since there is still appreciable mortality from delayed diagnosis. In developing countries where TB is still a burden, a chest radiograph is mandatory in patients with prolonged fever even without respiratory symptoms. Initiating empiric TB therapy is entirely justified as soon

as miliary shadowing is documented. Standard regimens containing both isoniazid and rifampicin are used (Nehaul, 2003). The duration of treatment is usually six months. The exact role of adjunctive corticosteroid treatment is unclear (Sharma *et al*, 2005). However, it may be beneficial in patients with tuberculous meningitis, tuberculous pericarditis, and miliary tuberculosis with refractory hypoxemia (Nehaul, 2003; Golden and Vikram, 2005). In this case, corticosteroid was started in view of the cerebral involvement and neurological manifestations associated with the miliary nature of the disease.

In conclusion, disseminated TB is associated with significant morbidity and mortality due to its protean manifestations. In a country wherein TB is endemic, a chest radiograph is a mandatory investigation in a patient with prolonged fever even without respiratory symptoms. Our case report is important for its multisystem involvement, misleading the physicians in spite of living in a country with a high incidence of TB patients. This is even more a challenge in non-TB endemic countries, since no country is safe unless every country is safe.

REFERENCES

- Beers MH, Berkow R. The Merck manual of diagnosis and therapy. 17th ed. New Jersey: Merck Research Laboratories, 1999.
- Chung DK, Hubbard WW. Hyponatremia in untreated active pulmonary tuberculosis. *Am Rev Respir Dis* 1969; 99: 595-7.
- Golden MP, Vikram HR. Extrapulmonary tuberculosis: an overview. *Am Fam Physician* 2005; 72: 1761-8.
- Hopewell PC, Bloom BR. Tuberculosis and other mycobacterial diseases. In: Murray JF, ed. Textbook of respiratory medicine. Vol 1. 3rd ed. Philadelphia: WB Saunders, 2000: 1043-105.
- Lessnau KD, de Luise C. Miliary tuberculosis. Emedicine, Last updated October 3, 2006. [Cited 2007 March 2]. Available from: URL: <http://>

MULTI-ORGAN TUBERCULOSIS DIAGNOSTIC DELAY

- www.emedicine.com/med/topic1476.htm
- National Tuberculosis Programme. Tuberculosis in Nepal. Katmandu: Ministry of Health, 1995.
- Nehaul LK. Tuberculosis. In: Walker R, Edwards C, eds. Clinical pharmacy and therapeutics. 3rd ed. Edinburgh: Churchill Livingstone, 2003: 583-95.
- Raviglione MC, O'Brien RJ. Tuberculosis. In: Braunwald, Fauci, Kasper, *et al.* Harrison's principles of internal medicine. 15th ed. McGraw-Hill, 2001: 1024-35.
- Sharma SK, Mohan A, Sharma A, Mitra DK. Miliary tuberculosis: new insights into an old disease. *Lancet Infect Dis* 2005; 5: 415-30.
- Slavin RE, Walsh TJ, Pollack AD. Late generalized tuberculosis: a clinical pathologic analysis and comparison of 100 cases in the preantibiotic and antibiotic eras. *Medicine* 1980; 59: 352-66.