

## A CASE OF EXFOLIATIVE DERMATITIS IN A CAPTIVE SOUTHERN WHITE RHINOCEROS (*CERATOTHERIUM SIMUM SIMUM*)

Luc Bauwens, Charles De Vroey, Ph.D., and Walter De Meurichy, D.V.M.

**Abstract:** A southern white rhinoceros (*Ceratotherium simum simum*) exhibited at the Antwerp Zoo suffered from exfoliative dermatitis. Treatment with topical antibiotics was ineffective. Large numbers of *Malassezia pachydermatis* and *Candida parapsilosis* yeast cells were found in the lesions by light microscopy and culture. Application of natamycin solution b.i.d. for 1 mo and s.i.d. for another month resulted in complete recovery. In contrast to earlier reports that characterized microorganisms isolated from rhinoceros skin lesions as secondary invaders, the positive response to natamycin treatment reported here suggests the pathogenicity of both *M. pachydermatis* and *C. parapsilosis*.

**Key words:** Southern white rhinoceros, *Ceratotherium simum simum*, exfoliative dermatitis, *Malassezia pachydermatis*, *Candida parapsilosis*, natamycin.

### INTRODUCTION

*Malassezia (Pityrosporum) pachydermatis* (= *P. canis*) is a lipophilic yeast that reproduces by unipolar budding and is a commensal on the skin and in the ears of several species. It is often associated with otitis externa in cats and dogs and has been recognized as a cause of chronic dermatitis in dogs.<sup>1</sup>

*Malassezia pachydermatis* was first isolated in 1924 from an extensive inflammation of the skin in an Indian rhinoceros (*Rhinoceros unicornis*) at the Philadelphia Zoo that was suffering from "dermatitis exfoliativa."<sup>7</sup> The disease was considered a physiologic annual recurrent dermatitis, although severe hyperemia of the underlying dermis was noticed.<sup>8</sup> Subsequent reports attributed this exfoliation to excessive drying of the epidermis, and the *Malassezia* invasion was considered secondary.<sup>3</sup> In this paper, we describe a similar case of exfoliative dermatitis as a result of combined *M. pachydermatis* and *Candida parapsilosis* infection in a southern white rhinoceros (*Ceratotherium simum simum*).

### CASE REPORT

During the summer of 1993, a male white rhinoceros, exhibited at the Antwerp Zoo since 1974, developed skin lesions on its back. The lesions appeared to be abrasions and were cleansed with chlorophene/lauryl sulfate solution (Neo-Sabeny<sup>®</sup>, Sterling Health, Brussels, Belgium). Oxytetracycline HCl/polymyxin B sulfate ointment (Terramycine<sup>®</sup>, Pfizer, Brussels, Belgium) was applied every 3 days for several weeks. There was no clinical improvement, and several new dorsal lesions appeared (Fig. 1). These lesions gradually enlarged to irregular dermal erosions up to 20 cm in diameter, with detaching edges and a hyperemic surface covered with brown-red exudate (Fig. 2). The otherwise-calm animal was nervous and pruritic. Swabs were taken from the exudate, and pieces of broken-off epidermis were collected. Direct microscopic observation of the samples revealed a large number of small, oval, budding yeast cells together with numerous larger, oval to round yeast cells. In methylene blue-stained smears, *Malassezia* sp. were recognizable by their size, shape, and unipolar budding. Gram-stained smears were negative for bacteria, and acid-fast organisms could not be demonstrated with Ziehl-Neelsen staining. The specimens were streaked onto plates of blood agar, Mac-

From the Department of Veterinary Services, Royal Zoological Society of Antwerp, Koningin Astridplein 26, B-2018 Antwerp, Belgium (Bauwens, De Meurichy); and the Laboratory for Mycology, Institute of Tropical Medicine "Prince Leopold," Nationalestraat 155, B-2000 Antwerp, Belgium (De Vroey).



**Figure 1.** A southern white rhinoceros (*Ceratotherium simum simum*) with cutaneous lesions on its dorsal side associated with combined *Malassezia pachydermatis* and *Candida parapsilosis* infection.

Conkey agar, Sabouraud dextrose agar fortified with kanamycin, penicillin, and cycloheximide (incubated at 37°C), and Sabouraud dextrose agar fortified with kanamycin and penicillin (incubated at 25°C). Within 1 wk, massive growth of small white colonies that became cream yellow with age appeared on Sabouraud agar at 37°C. These colonies were identified as *M. pachydermatis*. Sabouraud agar at 25°C demonstrated rich growth of a *Candida* sp., identified with conventional methodology as *C. parapsilosis*. Bacteria were not isolated. Histopathologic examination of a punch biopsy indicated exudative epidermitis.

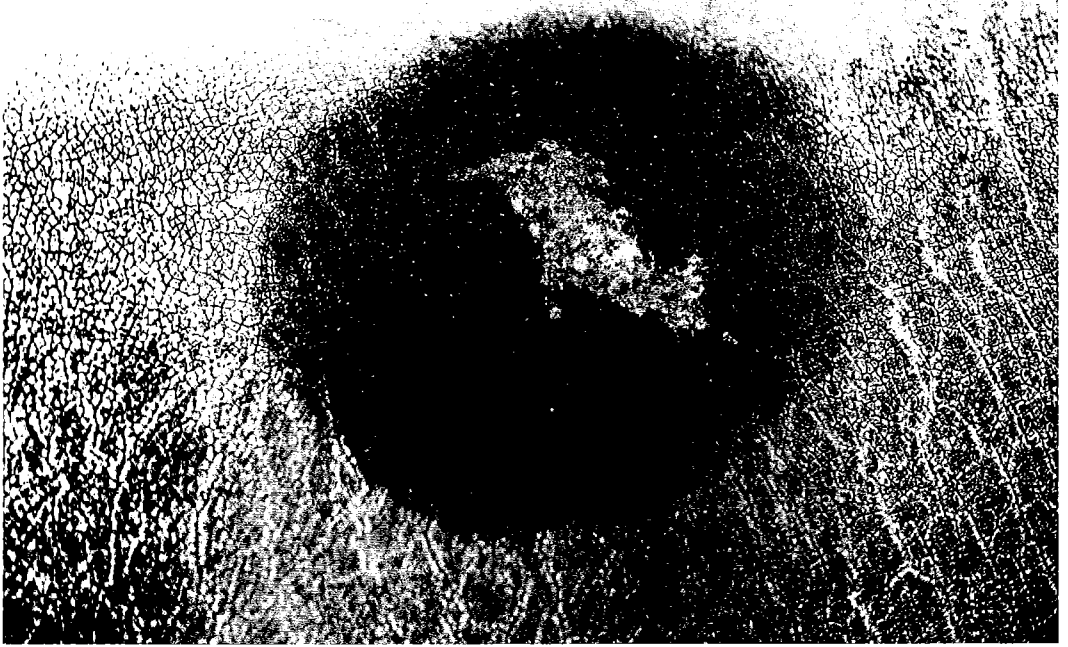
The animal was treated with a 2.5% natamycin solution (pimaricin) (Pimafucin®, Brocades Pharma B.V., Leiderdorp, Netherlands), a polyene antifungal agent. In the USA, natamycin is only available as an ophthalmic preparation for the treatment of fungal keratitis. In Belgium, it is prescribed pri-

marily for the treatment of oral candidiasis. This solution was applied b.i.d. over the lesions. After 1 wk, no further extension of the lesions occurred and the dermis dried up. Microscopic examination of lesions swabs still revealed *M. pachydermatis*, but no organisms could be cultured at this time. Within 1 mo, examination of the skin surface revealed a new epidermal layer. Treatment was reduced to s.i.d. application for another month, resulting in complete recovery.

## DISCUSSION

Free-ranging and newly captured black rhinoceros (*Diceros bicornis*) often have ulcerating skin lesions caused by *Stephanofilaria dinniki*, a filarial nematode.<sup>5,6</sup> However, no parasites have been noted in ulcers of captive black rhinoceros. The parasite is host specific and has never been reported from sympatric white rhinoceros.<sup>2</sup>

Mucosal and cutaneous ulcers are prev-



**Figure 2.** Cutaneous lesion on a southern white rhinoceros prior to natamycin treatment. Note the dark zone as a result of previous antibiotic ointment application.

alent in captive black rhinoceros. Cutaneous plaques progressing to pustules and then ulcers are distributed on pressure points and the periphery of appendages. In severe cases, ulcers extend over the abdomen and the chest. This primary epithelial disease does not appear to be associated with fungal or bacterial infection, and the etiology of the syndrome remains unknown.<sup>3,4</sup>

Generally, the thin epidermal layer of rhinoceros skin is easily damaged, and drying can cause fissures that may allow the invasion of pathogens. Skin disease in rhinoceroses could indicate an underlying pathologic condition (e.g., a metabolic defect) if a pathogen capable of causing the lesions cannot be isolated; isolated bacteria and fungi have usually been considered secondary invaders.<sup>2,3</sup>

In the original description of exfoliative dermatitis in an Indian rhinoceros from

Philadelphia, the lesions were apparently more extensive than those in the present case; the skin became detached and curled up along the fissures, but the central parts remained adherent for a considerable time.<sup>7</sup> In the present case, the lesions were restricted to the dorsal side of the animal, and exfoliation spread from the center, resulting in dermal erosions.

In 1924, another rhinoceros (species not reported) at the New York Zoological Garden had a condition comparable to that of the Indian rhinoceros. In the epithelial scales from both animals, the same yeast cells and mycelial fragments were demonstrated; a slow growing new species named *Pityrosporum* (now *Malassezia*) *pachydermatis* and a rapid growing *Monilia* sp. provisionally identified as *M. ellipsoideus* predominated.<sup>7</sup> The Philadelphia rhinoceros was successfully treated with 1% salicylic acid in lard. However, after 1 yr the con-

dition recurred, and the exfoliation was thought to be a normal physiologic process.<sup>8</sup> Greasy substances such as vegetable oil or baby body lotion are regularly applied to captive animals to prevent skin lesions caused by excessive drying of the epidermis. Although the primary cause of the skin lesions in the Antwerp rhinoceros remains unclear, the application of antibiotic ointment may create an ideal environment for yeast and other fungi.

*Malassezia* sp. may be part of the normal flora of rhinoceros skin; it has been isolated from the healthy skin of Indian and other white rhinoceros at the Antwerp Zoo. In the three cases discussed, *Malassezia pachydermatis* was associated with another yeast species. Because the tentative identification of "*Monilia ellipsoideus*" was based only on morphology and not on physiologic criteria (which were introduced some years later), it is impossible to know what species was actually involved.

The animal at the Antwerp Zoo was treated with natamycin instead of other polyenes and azole derivatives on the basis of in vitro susceptibility results. The excellent response and healing suggest that the yeasts were primary pathogens. The female white rhinoceros sharing the same ground was not affected, and in previous years neither of these two animals suffered from a similar condition. In view of these findings, we recommend cessation of oily substance application for skin injuries. Pure water sprays

or wallows could be used to protect the skin from desiccation.

*Acknowledgment:* We are indebted to Brocades Pharma B.V., Yamanouchi Group, Brussels, Belgium, for providing natamycin (Pimarufin®).

#### LITERATURE CITED

1. Dufait, R. 1983. *Pityrosporum canis* as the cause of canine chronic dermatitis. Vet. Med. Small Anim. Clin. 78: 1055-1057.
2. Jones, D. M. 1979. The husbandry and veterinary care of captive rhinoceroses. Int. Zoo Yearb. 19: 239-252.
3. Jones, D. M., and L. R. Thomsett. 1972. A short review of the diseases of rhinoceros skin with case reports on an exudative dermatitis of the white rhinoceros (*Ceratotherium simum*). Proc. Int. Symp. Zoo Anim. Dis. 14: 227-231.
4. Munson, L. 1993. Mucosal and cutaneous ulcerative syndrome in black rhinoceros (*Diceros bicornis*). Proc. Int. Conf. Rhinoceros Biol. Conserv. Pp. 354-356.
5. Round, M. C. 1964. A new species of *Stephanofilaria* in skin lesions from the black rhinoceros (*Diceros bicornis*) in Kenya. J. Helminthol. 38: 87-96.
6. Schulz, K. C. A., and E. G. Kluge. 1960. Dermatitis in the black rhinoceros (*Diceros bicornis*) due to filariasis. J. S. Afr. Vet. Med. Assoc. 31: 265-269.
7. Weidman. 1925. Exfoliative dermatitis in the Indian rhinoceros (*Rhinoceros unicornis*), with description of a new yeast species, *Pityrosporum pachydermatis*. Rep. Lab. Mus. Comp. Pathol. Zool. Soc. Philadelphia. Pp. 36-44.
8. Weidman. 1926. Recurrence of dermatitis exfoliativa in Indian rhinoceros (*Rhinoceros unicornis*). Rep. Lab. Mus. Comp. Pathol. Zool. Soc. Philadelphia. Pp. 28-29.

Received for publication 4 May 1994